Abbassa Int. J. Aqua., V0l.6 No.(2) 2013. *475-504*

SEA LICE (CALIGUS) INFESTATION AND ITS ROLE IN ENHANCEMENT OF BACTERIAL INFECTION IN SEA BASS (*DICENTRARCHUS LABRAX*) IN DAMEITTA GOVERNORATE

Mohamed E. Abou Elatta

Fish Health Department, Central Laboratory for Aquaculture Research, Agricultural Research Center, Ministry of Agriculture, Egypt.

Received 2/ 7/ 2013 *Accepted 15/ 8/ 2013*

Abstract

One hundred clinically infected Sea bass (*Dicentrarchus labrax*) 80 ±5gm and 15 ±2cm in length were collected from earthen pond from Tri-angular of El Deeba, Damietta Governorate and subjected to clinical, postmortem investigation, haemotological, bacteriological, parasitological and histopathological examination. Also, the physicochemical analysis of water pond holding Sea bass (*Dicentrarchus labrax*) was recorded. The clinical investigation observed were lethargic, restlessness, cease to food, excessive mucus, nervous manifestation and jumping over water surface infested fishes were rubbed themselves on solid substrate in attempt to dislodge the crustacean parasites which appeared attached to gills, skin & fins rays, head region and buccal cavity. Opaque of skin, diffused hemorrhage scattered on gill cover, around the mouth, pre anal, caudal and pectoral region, mechanical damage of skin, erosion, sometimes reach ulceration of skin were observed. Infested fishes were showed gasping of air, swimming near to water surface and accumulated around the water inlet (High current water). In severe cases, fish was observed with mechanical damage of the skin, erosion, sometimes ulceration. The postmortem finding showed presence of large number of caligus on the body surface, also occurred in oral cavity and under gills cover. In some cases, the gills were pale with brown focci look like marbling appearance, pale liver, congested spleen and kidney. Other cases showed congested liver and enlarged gall bladder and distended with bile. The haemotological finding of infested Sea bass with caligus showed decreasing in PCV, Hb, total protein and calcium while increasing in glucose, ALT and AST. The result of bacteriological examination revealed the isolation of *Vibrio alginolyticus* and Streptococcus species. *V. alginolyticus* was isolated with 35% from infested fish with Caligus. *V. alginolyticus* was isolated with high percent from necrotic skin, gills, liver and kidney respectively

while in low percentage from spleen and blood. The pathogenicity of isolated *V. alginolyticus* was done and recorded. The result of antibiogram revealed that, Florefenicol, Enrofloxacin, Nalidixic acid and Ciprofloxacin were highly effective against *V. alginolyticus.* The parasitological examination revealed that the crustacean parasites were identified as copepods of *Caligus minimus* and *Caligus carangis*, the prevalence of infestation was 100% and the mean number of individuals per host was twenty five. The histopathological finding of infested skin and gills of infested Sea bass (*Dicentrarchus labrax*) were studied. The trial of treatment by using Ivermectin 1% (Iverzin lotion 1%) 6ml/L for 5 minutes gave a good results in elimination of adult caligus and immuture developmental stages from infested Sea bass (*Dicentrarchus labrax*) .

INTRODUCTION

Sea bass (*Dicentrarchus labrax*) is marine fish with high economic value in Mediterranean aquaculture industry Marine fishes are preferable than freshwater fishes due to the former are rich in trace elements as phosphorous and iodine which are essential for cell metabolism. Sea bass *(D. labrax*) Culture are recently in Egypt and need for progressive development and there is still much to be learned with regard to health and disease prevention. the success in aquaculture industry depend up on the selection of reared species of fish, healthy aquatic environment and realizing the relationship between fish, their environment and pathogens. Sea bass has a range of organisms that parasitize and cause the disease of it. Parasitic infestation represent the majority of the Known infectious diseases affecting fish, Ragias *et al.* (2004); Timi and Lanfranchi (2006); Woo (2006) and Noga (2010). In marine cultured fish, 54% of copepod infestations are caligids Costello, (2006). The caligidae is the largest family of parasitic copepoda which include more than 450 species classified into 33 genera Boxshall and Halsey (2004). The caligidae of the genus caligus contains the highest number of species known to parasitize fish Johnson *et al.* (2004). The losses associated with caligus infestation are the result of direct mortality

due to immune state decreasing and suppressing and allow secondary bacterial infection occur Lin *et al*. (1994) and Ho (2000). Several pathogenic vibrio have been isolated from outbreaks affecting fish species Pujalte *et al*. (2003) Zorrilla *et al*. (2003b). *Vibrio alginolyticus* have been reported in Sea bream *(Sparus aurata)* and Sea bass (*Dicentrarchus labrax*) and other vibrio species Ben- Kala Nakbi *et al*. (2006); Jale *et al*. (2008) and Anwar *et al*. (2010). The present study directed towards further understanding of marine Sea bass fish in Triangular of El Deeba, Damietta Governorate. the objective were decided to throw the light on the clinical, postmortem, isolation and identification of copepod caligus infestation and related bacteria, histopathological and haematological finding and trial to control.

MATERIAL AND METHODS

Naturally infected fish:

A total number of one hundred. moribund and disease Sea bass *(D. Labrax*) weighted 80 gm. ±0.5 and 18 cm ±0.5 in length were collected from earthen pond from Triangular of El Deeba, Damietta Governorate and immediately were subjected to full clinical examination, haematological, postmortem finding, parasitological, bacteriological, histopathological investigation.

Water quality analysis:

The physicochemical analysis of water holding Sea bass (*D. Labrax*) were done in the field immediately for measuring the water parameters, which includes temperature, dissolved oxygen (D.O), Saturation %, pH, Salinity, total solid, nitrate and nitrite.

Clinical investigation and Postmortem examination of moribund and diseased Fish:

Moribund and clinically diseased Fish were properly examined for any external clinical abnormalities, lesions and clinical alterations on the skin, scales, eye, abdomen, fins and any abnormal behaviors. The postmortem examination was done on moribund Fish or freshly dead Fish to examine all internal organs including gill, liver, Kidney, spleen and intestine. The clinical investigation and postmortem examination were done according to Amlacher (1970).

Haematological Finding:

Blood samples were taken from healthy and infected Sea bass *(D- Labrax)* from caudal artery under anathestic by Ms 222 to determine the blood parameters as packed cell volume (PCV), hemoglobin (Hb), total protein, Albumin, globulin, Albumin globulin ratio, Aspartate Amino transferase (AST) and Alanin Amino Transferase (ALT), also blood smear were prepared and fixed with methanol and stained with Gemisa stain to detect any blood parasites.

Bacteriological examination:

Samples for bacteriological examination collected under aseptic precaution from gills, Liver, spleen, blood, kidney skin ulcer and inoculated onto Tryptic Soy Broth (T.S.B) with 2% sodium chloride and streaked on TS agar, the suspected purified colonies were picked up and streaked over specific media as Thiosulphate Citrate Bile salt Sucrose Agar (TCBS) (Biolife, Milan, Italy, supplemented with 2% Nacl the inoculated media were incubated at 25°C for 24-48 hrs, the isolates were subjected to taxonomical analysis according to Beregy's (1994).

Parasitological examination:

Macroscopic examination was done for detection of any abnormalities indifferent parts of the fish body by naked eyes and hand lens. Skin, fins, gills, eyes and opercula were dissected and examined for presence of parasitic crustaceans. The attached crustaceans to gills, skin, fins, head region and buccal cavity were carefully removed with the help of needle and soft brush.

Microscopic examination:

Removed crustaceans put under a low power binocular microscope, washed with distilled water. they were fixed in 3% formal saline , preserved in equal amount of 70% alcohol 5% glycerin and permanent amounts were prepared by passage in descending grades of alcohol (70% , 50% and 30%) , cleared in glycerin and mounted in glycerin – gelatin according to lucky (1977). The isolated copepods species were identified according Kabata (1988); Ho *et al*. (2000) and Ho and Lin (2004)

Pathogenicity test:

A total number of thirty Sea bass (*D. Labrax*) were collected apparently healthy and holding in glass aquaria (50×50×100cm), continuous aeration was maintained using an air pump and fed with 5% body weight commercial ration and divided into 2 group, each group contain 10 fish (10 fish / group), 1st group injected experimentally intraperitoneal I/P with 1×10 Cfu/ml of isolated strains and skin scarification S/S of fish (Sea bass) in 2nd group according to Ben- Kala Nakbi., *et al.* (2006) and 3rd group injected with same dose with sterile saline, all groups were observed daily for 10 days to record any abnormal behaviors, clinical signs, daily mortalities and re-isolation of injected strains were done .

Histopathological examination:

Samples for histopathological examination were freshly taken from skin, gills, liver, kidney and spleen of moribund Sea bass, the techniques were done according to Roberts (2001).

Antibiogram Senstivity:

Antibiogram sensitivity test was done to the limits given by Schaperclaus *et al.* (1992) using disc diffusion method on Muller's Hinton agar medium and interpretation zones of inhibition were recorded. The antibiotic discs were Ciprofloxacin, Enrofloxacin, Tetracycline, Colistin sulphate, Rifampin, Florefenicol, Lincomycin, Pencillin and Nalidixic acid.

Treatment trials:

Chemical treatment was done by using Ivermectin 1% (Iverzine lotion). Infested Sea bass collected (40 infested Sea bass with copepod caligus) and holding in glass aquaria (50×50× 100 cc), same salinity and divided into 4 group 1st control positive infested Sea bass. The 2nd group treated with 2ml/L (200ppm) of Ivermectin 1% for 5 minutes, 3rd group 4 ml /L (400ppm) of Ivermectin 1% for 5 minutes and 4th group 6 ml/L (600ppm) Ivermectin 1% for 5 minutes. All aquaria must be aerated to adjust the dissolved oxygen.

RESULTS

Results of physicochemical analysis of water:

The results as shown in Table (1), temperature is 29°c, Dissolved Oxygen 3.6 mg/L, saturation 52.5% total solid 140 mg/L, nitrate (No_3) 0.2 mg/L, nitrite (No_2) 0.004 mg/L and the salinity of water is 28 ‰.

Table (1). Physico-chemical analysis of water holding Sea bass *(D labrax).*

Water parameter									
Temperature	**Salinity**	**Ph**	**DO**	**Saturation**	**Alkalinity**	**NO2**	**NO3**	**PO4**	**TS**
29°c	28%	7.8	3.6 mg/L	52.5 %	100 mg/L	0.004 mg/L	0.2 mg/L	0.2 mg/L	140 mg/L

DO = Dissolved oxygen, NO2 = Nitrite, NO3 = Nitrate, PO4 = Phosphate, TS = Total solid.

Results of clinical signs:

The results of clinical investigation of sea bass *(D. Labrax)* in cultured pond were, swimming near to the surface of water, gasping of the air and accumulation around the water inlet. Lethargic, Listless, off food, nervous signs, infested fish, easily catchable and can not response to external stimuli. Infested sea bass with Caligus were rubbed themselves against solid substrate, excessive mucus secretion allover the body surface. Caligus appeared attached to sea bass *(D. Labrox)* in different area of the body, gills, Skin at ventral aspect, fins, eyes buccal Cavity, turbidity of the eye, opaqueness of the skin, frayed fins, diffused hemorrhage on gill cover, behind pectoral fins around the mouth anal region and tail part. In sever infested cases, fish were observed mechanical damage of the skin and erosions, as shown in plate (1): photos 1-5).

Postmortem findings:

Infested fish showed presence of large number of caligus on the body surface, fins, buccal cavity, eye, attached to gills and under gill cover, hemorrhage under gill cover, congested gills and pale and friable in other cases, gill cover an able to closed on gills due to large number of caligus as shown in plate (1): photos (1&2). Internally, showed congested

liver, spleen, kidney, gall bladder distended with bile secretion, accumulation of blood tinged exude in abdominal cavity and the intestine showed free from food and hemorrhaged. Plate (1): photo (6).



Plate (1). Photos 1-6.External accumulation of large number of caligus, erosion, haemorrhage and congestion internal organs of affected Sea bass with caligus and bacteria.

Results of haematological finging:

The blood parameters and chemistry of healthy and infested sea bass *(D- Labrax)* as shown in Table (2), it cleared that decreasing in packed cell volume, haemoglobin, total protein, albumin, globulin, albumin / globulin ratio and calcium while increasing in glucose, aspartate amino transferase and alanin amino transferase in infected sea bass than healthy sea bass. Microscopic examination of blood smear showed no blood parasites.

Table (2). Blood parameters and chemistry of healthy and infected Sea bass.

Blood Parameters	PCV	Hb	Tp	A	G	A/G	Ca	Gl	ALT	AST
Healthy Fish	26.3	5.4	4.4	1.45	2.95	0.491	7.6	67	34	78
Infected fish	24.2	3.9	3.8	1.23	2.57	0.478	7.1	95	38	82

PCV: packed cell volume; Hb: hemoglobin; Tp: total protein; A: albumin; G: globulin

Results of bacteriological examination:

The cultural, morphological and biochemical characters recorded in Table (3) according to Bergey's (1994), it revealed the isolation of gram negative bacterial isolates, identified as *Vibrio alginolyticus* and other gram positive streptococcus species. As shown in Table (4), the percentage of bacterial infection reach 35% from total infested sea bass *(D. Labrax)*, while the percentage of caligus infestation reach 100%. The distribution of isolated bacteria in different organs and tissues of infected sea bass *(D. labarax)* as shown in Table (5), it showed that *V. alginolyticus* recovered in total 102 isolates with high number from liver, 29 isolates (28.43%), kidney 21 isolates (20.58%), skin 16 isolates (15.68%), gills 12 isolates (11.76%), spleen 13 isolates (12.72%) and blood 11 isolates (10.78).

Table (3). Morphological and biochemical characters of isolated *vibrio* from infected Sea bass *(D labrax).*

Test	Reaction
Gram stain	- ve
Mortality	swarming mortality
TCBS agar	yellow colonies
Oxidase	+ ve
O/F	+ Fermentive
Growth at	
29°c	+ ve
37°c	+ ve
43°c	+ ve
Growth on NaCl%	- ve
0%	+ ve
3%	+ ve
5%	+ ve
7%	+ ve
10%	+ ve
Indole	+ ve
V.P	+ ve
M.R	+ ve
H2s production	- ve
Citrate utilization	+ ve
Arginin hydrolysis	- ve
Catalase	- ve
Gelatin liquefaction	+ ve
Fermentation of sugar	
glucose	- ve
arabinose	- ve
sucarose	+ ve
lactose	- ve

Table (4): The incidence of infestation and infection in Sea bass *(D. labrax).*

Total No. of examined fish	No. of infested fish with caligus	No. of infected fish with bacteria	No. of samples for bacteriology	Total isolated
100	100	35	210	102
%	100	35		48.57

Table (5): Prevalence and distribution of isolated *V. alginolyticus* in different organs and tissues of infected Sea bass *(D labrax).*

No. of isolates	Gills		Skin		Liver		Kidney		Spleen		Blood	
	No.	%	No.	%	No.	%	No.	%	No.	%	No.	%
102	12	11.76	16	15.68	29	28.43	21	20.58	13	12.74	11	10.78

Results of parasitological examination:

The parasitological examination revealed that the caligus belonged to the copepoda, family caligidae and were identified as *Caligus minimus* plate (2) photo 1, *Caligus carangis* plate. (2) Photo (2) and some immature developmental stages. Plate (2) photo 3&4 were found according to the morphological characteristic.

The morphological description of *Caligus minimus:* The body length of the male (♂) 5.9mm and the width reach 2.9mm. the cephalothorax is nearly as long as wide, abdomen is one segment, genital complex contain caudal rami which are longer than wide as shown in plate (2) photo 5&6, the body length of female (♀) measure 5.5mm and 2.6mm in width, as shown in plate (2) photo7 showed lunule, the first and second antennae, cephalothorax, cephalic zone, two lateral zones, and thoracic zone are clearly identified. The posterior segment of cephalothorax is jointed with an apron that includes the tagma and third leg. The length of tagma is greater than thoracic zone of shield. In the genital segment, the oviduct channel, intestine and immature eggs are clear. The last part of *Caligus minimus* (♀) is abdomen (posterior tagma), which includes an abdomen, and caudal rami, two egg column (Right and left), the left egg column includes 19 eggs but right egg column had 16 eggs. The shape of the eggs is cylindrical in shape as shown in plate (2) photo 8&9. The morphological description of *Caligus carangis*: The body of the female (♀) measured 2.6mm in length and 1.03mm in width,

cephalothorax is nearly as long as wide and the anterior part of the body contain two eyes, 1st and 2nd maxilla and claws plate (2) photo 11. The posterior tagma (abdomen) has one segment and nearly 3times longer than wide , the caudal part of the female contain two large egg column (Right and left) each one includes 22 eggs which are cylindrical in shape as shown in plate (2) photo 11&12. The prevalence of caligus infestation in sea bass *(D. Labrax)* reaches 100% as shown in Table (4).



Plate (2). Photo 1-12.Light micrograph of some developmental stages and adult male & female of *Caligus minimus* and *Caligus carangis*.

Results of pathogenicity:

As shown in **Table (6)**, The Signs of the disease were seen after 24hrs post intarperitoneal injection (I/P) with *V. alginolyticus*, included inflammatory change at the site of inoculation, hemorrhage allover the body specially at the base of the fins, congested gills, liver, spleen and Kidney. The reisolation of the *V. alginolyticus* on specific media was obtained. It cleared that I/P route of injection was high effect than skin scarification (S/S). I/P route cause 100% mortality among experimentally injected sea bass within fourth days post injection, while S/S cause 100% mortality with in 6th days post injection.

Table (6): Pathogenicity and mortality rate of experimentally infected Sea bass *(D. labrax)* with *V. alginolyticus*.

Group	Dose of injection	Rate of injection	Fish No.	Dead fish during 10days										No. of dead	Mortality rate %
				1st	2nd	3rd	4th	5th	6th	7th	8th	9th	10th		
1st	1×10^{7} Cfu	I/P	10	0	2	4	4	0	0	0	0	0	0	10	100%
2nd	1×10^{7} Cfu	S/S	10	0	2	2	3	2	1	0	0	0	0	10	100%
3rd	Sterile saline	I/P	10	0	0	0	0	0	0	0	0	0	0	0	0

Results of histopathological examination:

The skin of infected sea bass *(D. Labrax)* showed hyperplasia of the club cells of the epidermis, Congested and hemorrhagic dermis with excessive aggregation of round cells and melanomacrophage. Other lesions showed epithelial desquamation in the epidermis, the other epidermal cells suffered vacuolar degeneration and focal necrosis, the underling dermis was edematous with focal aggregation of melanomacrophage cells. The necrotic muscle infiltrated with

mononuclear leukocytes and some melanamacrophage, plate (3) photo 1. Gill, showed hyperplasia of the epithelial covering, beside congestion of branchial blood vessels and fusion of secondary lamellae, plate (3) photo 2&3. The liver showed lipid infiltration of the hepatocytes, congestion of the hepatoportal vein, central vein and congestion of the sinusoid and hyperplasia of the epithelial lining bile duct, plate (3) photo 4. Spleen showed separation of the spleenic capsule with multiple melanomacrophage cells and ulcerative area of depletion and proliferation of hemopiotic elements, plate (3) photo 5. Kidney showed congestion of some renal blood vessel and depletion of hemopiotic elements in the interstitial tissues. Collapse of glomerulli and edema of Bowman's capsule with degenerative change, plate (3) photo 6.

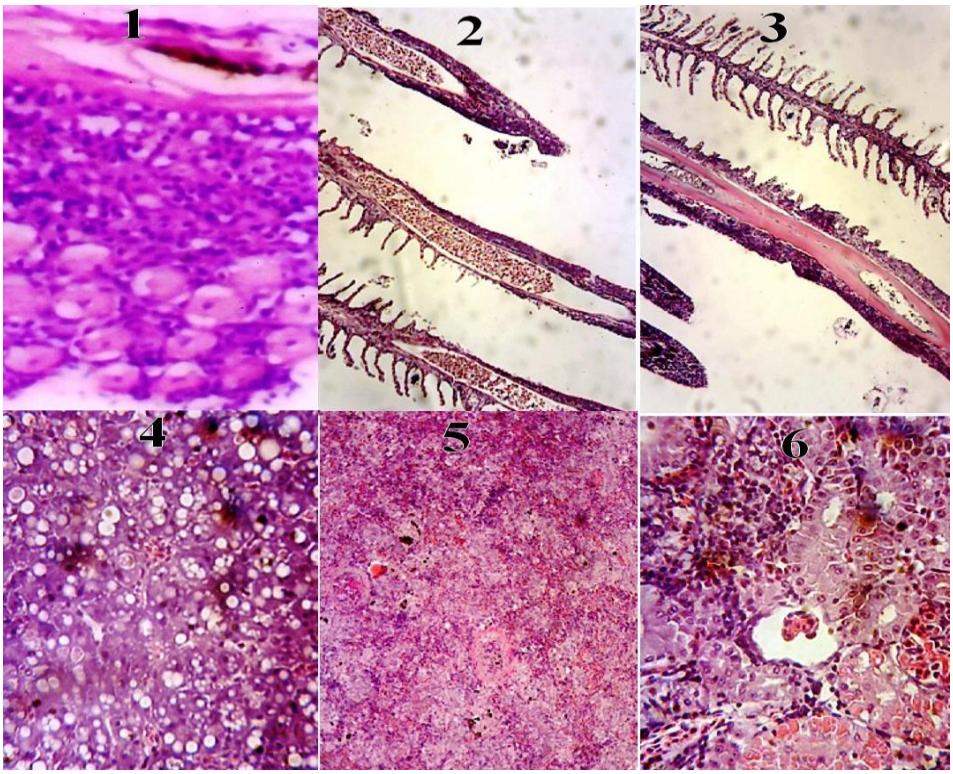

Plate (3). Photo 1-6. Histopathological changes of different organs of infected Sea bass (skin, gills, liver, spleen and kidney). (H&E)

Results of antibiogram sensitivity:

As shown in Table (7), *V. alginolyticus* isolated from Sea bass *(D-Labrax)* was sensitive to Florfenicol , Ciprofloxacin , Enorofloxacin and Nalidixic acid but it was resistant to Colistin sulphate , lincomycin , pencillin and moderate sensitive to Tetracycline.

Table (7): Antibiogram of *V. alginolyticus* isolated from Sea bass *(D. labrax)*

Antbiotic disc	Code symbol	Concentration (µg)	Reaction
Ciprofloxacin	Cip5	5	(S)+++
Colistin Sulphate	CL10	10	R
Penicillin	P10	10	(R)
Florefenicol	Ffc30	30	(S)+++
Lincomycin	L2	2	R
Nalidixic Acid	NA30	30	(S)++
Enrofloxacin	Enr10	10	(S)+++
Tetracycline	Te30	30	±

Results of treatment trials:

The trial for treatment of naturally infested Sea bass with Caligus by using different concentration of Ivermectin 1% (lotion 1%) bath for 5 minutes, in a concentration of 2ml / liter (200 ppm) had no effect on adult and immature stage of Caligus while 4ml / liter had effect on the adult but the immature stage still active, the complete elimination of adult and immature stages of Caligus resulted by using 6 ml / liter (600 ppm) and had no effect on the health state of treated fish as shown in Table (8).

Table (8): Results and condition of Sea bass *(D. labrax)* and copepods after treatment with different concentration of Ivermectin 1% and time of exposure to remove caligus from Sea bass.

Group	No. of fish	Treatment	Time of exposure	Concentration	Fish condition	Copepod condition
1st	10	Ivermectin 1%	5 min	2ml/L (200 ppm)	Infested	Active
2nd	10	Ivermectin 1%	5 min	4ml/L (400 ppm)	Infested	Inactive
3rd	10	Ivermectin 1%	5 min	6ml/L (600 ppm)	Free	Dead

DISCUSSION

Sea bass *(D. Labrox)*, is the marine fish with economic value in Mediterranean aquaculture industry so the success in aquaculture industry depend upon the selection of rearing species of fish, healthy aquatic environment and realizing the relationship between fish and pathogen or causative agent, regarding the physics- chemical analysis of water holding sea bass *(D. labrax)*, they were in the normal limit published by A.P.H.A (1985& 2005). With exception, slight decreasing in dissolved oxygen. The main clinical investigation of affected sea bass showed that, swimming near to water surface, lethargic, listless, gasping of air, accumulation around water inlet and nervous manifestation, and these signs due to attachment of caligus with sea bass specially gills leading to loss of respiratory surface area. These results agree with, Costello, (2009); Abou Elatta and Walaa (2012); Laster and Hayward (2006) and Tansel *et al*. (2012). Excessive mucus secretion due to irritation, infested sea bass with caligus rubbed themselves against solid substrate to try dislodge of attached coligus from their body, infested sea

bass with caligus and secondary bacterial infection accumulated around high water current at water inlet and gasping of air at water surface, these due to contact of caligus to gill filaments causing gill damage, destruction of gill tissue, causing inflammation and thickening of local epithelial layer, hemarrhage, hemolysis, hyperaemia and hyperplasia and death occur, also secondary bacterial infection were occure and cause septicemia and death, these results were nearly similar to that recorded by Paperna, (1986); Ragias *et al*. (2004); Laster and Hayward (2006); Costello, (2009) and Eissa *et al*. (2012), Opaqueness of the Skin, Frayed Fins, haemorrhagic spats scattered on different parts of the body of infested sea bass, sometime diffused haemorrhage, erosion and ulceration, these due to actively movement of pre adult and adult caligus on the surface of the skin of sea bass and penetration of the skin for feeding on blood stream causing considerable erosion open wound and ulcer, leads to physiological haemostasis including Osmotic stress anemia, hypoproteinaemia, immune state decreasing and suppressed, Facilitate invasion with secondary bacterial infection specially Vibrio species which inhibit the marine environment and ready occur, these results agree with Lin *et al*. (1994) Yambot and Lopez (1997); Hoo (2000); Johnson *et al.* (2004); Laster and Hayward (2006) Abou El Atta and walaa (2012). The postmortem examination of the affected sea bass, showed large number of pre adult and adult caligus on gills , under gill cover, buccal cavity, gills were pale with whitish brawn facci like marbling appearance, these results were recorded by Maather (2007), Eissa *et al*. (2012) and Tansel *et al*. (2012), but in some infected cases, showing congested gill, liver, spleen, kidney and accumulation of bloody tinged exudates in abdominal cavity these results occur due to septicemia as a results of secondary bacterial infection specially vibrio bacteria which secrete their power full toxins and proteolytic enzymes , the enlargement of liver pressed on bile duct and ductules causing accumulation of bile secretion in gall bladder, these results agree with

mentioned with Eissa *et al*. (2012). Hematological finding showed decreasing in PCV, Hb, total protein, Albumin, globulin and Albumin / globulin ratio, these due to caligus attached to skin, gills, buccal cavity and eyes and also penetrate the skin of infested sea bass, these leading to excessive mucous, irritation of the gills, opacity of the eye, restlessness, off food, erosion, haemorrhage causing anemia, hypo proteinaemia and decreasing immune state of infested fish while, the increasing in glucose these due to the fish infested with caligus became stressed and Adrenocortico trophic Hormon increased (ACTH) so, the glucose level in the blood increased also AST and ALT were increased . The bacteriological examination revealed the isolation of vibrio bacteria and other streptococcus. According to morphological, cultural, and biochemical characters identified as *Vibrio alginolyticus* inhibit brackish and marine water environment and highly distributed among wild and cultured fishes. vibriosis is a severe, economically important septicemic infection, these results were in similar that mentioned with Cheong *et al*., (1983) who recorded that vibriosis is a serious disease of farmed sea bass . Also *V. alginolyticus* have been reported in cultured sea bass *(D. Labrax)* and sea bream *(S. aurata)* and other vibrio species these reported by Zorrilla *et al.* (2003 b); Ben-Kala Nakbi *et al*. (2006); Jale *et al*. (2008); Anwar *et al*. (2010); Taghrid (2011) and Abou El Atta (2013). *V. alginolyticus* act as primary and secondary infected pathogen it isolated with high percentage from infested sea bass *(D. Labrax)* with caligus reach 35% from total infisted fish. It isolated with high percentage from liver, kidney, skin, spleen, gills and low percentage from blood stream, these due to caligus which cause erosion, hemorrhage, ulceration and excessive mucous secretion, which leads to decrease the immune state and suppressed the immune system, these accelerate and enhance the bacterial infection, *V. alginolyticus* secret cytotoxic and neurotoxic enzymes adhere to the skin , gills and intestinal mucosa of

infected sea bass, these results were similar that mentioned with, Egidias (1985) and Ben-Kala Nakbi *et al*. (2006). The first crustacean parasite is *Caligus minimus* isolated from *Caligus minimus* obtained from sea bass *(D. labrax)* reared in marine water, these result agree with Ozak (2006) and Tansel *et al*. (2012) who isolated same species from same host in turkey , also accepted with Popoutsoglou *et al*. (1996) and Ragias *et al* . (2004) who obtained same species from same host in Greece, also Pavoletti *et al*. (1999) isolated same species from host in Italy and Paperna and Laurencin 1979 isolated *Caligus minimus* from sea bass (D. Labrax) in France , and Sterud , (2002) recorded caligus minimus from buccal cavity of sea bass *(D. Labrax)* in Norway and Noor El-Deen *et al*. (2013) who isolated *Caligus minimus* from cultured Sea bass *(D. Labrax)* and Mullet *(Mugil cephalus)* in marine fish farms in Egypt. Affected sea bass with high percentage reach 100%, the description is defined according to Kabata (1979); Ho and Lin (2004); Ozak (2006) and Tansel *et al*. (2012). *Caligus minimus* was reported from sea bass *(D. Labrax),* considered as recent recorded in Egypt, the infested rate reach 25% copepods per fish these disagree with Tansel *et al*. (2012) who recorded 11-12 copepod per fish In present study majority of the *Caligus minimus* were adult, but also some developmental stages were found as copepod did stage, chalimus stager and per adult stage, these results agree with Lin *et al*. (1997) and Pike and Wadsworth (1999), who recorded that caligid copepods have direct life cycle consisting of 2 free living plankton, nouplius, 1 free swimming infections copepodid stage, 4 attached chalimus stages, 2 preadult stages and 1 adult stage . the second crustacean parasite was *Caligus carangis* which isolated from gills, buccal cavity, skin, fins and eyes, these results nearly similar to that mention of with Kabata (1988) and Eissa *et al*. (2012), who isolated *Caligus carangis* from sea bass *(Morone labrax)* from Suez canal, the percentage of infection reach 100% while infection rate with *Caligus carangis* reach 25 caligus 4 per fish , these results higher than the results

obtained by Eissa *et al*. (2012), who recorded that the total prevalence reach 47%, and disagree with Badawy (2001) who found no infestation in *(Morone Labrax).* The results of pathogenicity of *V. alginolyticus* to sea bass *(D. labrax)* it found that *V. alginolyticus* cause 100% mortality with in 4th day post injection I/P and 100% mortality by skin scarification with in 6th day and gave same lesions and signs, so *V. alginolyticus* considered to be primary and secondary bacterial infection, these results agree with Woo and Buruno (1999); Ben-Kala Nakbi *et al.* (2006); Taghrid (2011) and Abou El Atta (2013), who recorded that, the I/P injection of sea bream *(S. aurata)* with *V. alginolyticus* cause 100% mortality and gave the same lesions and signs. From the results of hitopathological findings the congestion and hemorrhages of the skin attributed to acute form of the disease, septicemia and toxemia of the causative agents leads to aggregation of the defense cells, the persist of these agents leads to desquamation of the cells while hypoproteinamia and decrease of the colloidal substance made breakdown of the cement substance of the endothelial cell of the blood vessels leads to passage of fluids to the surrounding medium. The gills showed focal hyperplasia was a simple response to the cellular necrosis, the congestion of the branchial vessels may be attributed to the reaction of the interleukins which cause vasodilatation of blood vessels. The process of acute inflammation was initiated by the action of the action of vasoconstriction amines on the microcirculation. The liver showed congestion of the central vein and lipid droplet degeneration in the hepatocytes, such hepatic lesions are indicative of septicemia as the liver was damaged by blood born pathogenic bacteria and its metabolites. The kidney showed collapse of the capillary tufts (Glomeruli) and could attributed to the presence of edematous fluids which accumulated in the Bowmn's capsules. The presence of hyaline droplet degeneration suggested the existence of glomerular disease which can present in the protein leakage in it, so, the

filtrates decreased and make pressure on the cells. The edema of the Bowmn's capsules resulted in hypoproteinamia, decrease the colloidal substances, breakdown the cement substance and the endothelial cells leads to the passage of fluids to the surrounding media. The histopathological changes in the organs of infected sea bream were agreed with the results mentioned by Marzouk *et. al*. (2009) and Avci *et al.* (2013). The results of antibiogram of isolated *V. alginolyticus* showed that, it was highly sensitive to Florefenicol, Ciprofloxacin, Enrofloxacin and Nalidixic acid and moderate sensitive Tetracycline while it was resistant to Colistin sulphate, Lincomycin and Pencillin, these results agree with Ben-Kala Nakbi *et al*. (2006); Enany *et al*. (2011); Abou El Att and Walaa (2012); Taghrid (2011) and Abou El Atta (2013). Ivermectin1% (lotion 1%) in a dose 6ml/L 600 ppm (0.06mg) gave effective results in controlling of caligus, these results nearly similar with Palmer *et al*. (1987); Smith *et al*. (1993) and Johnson and Margolis (1993) who reported the preliminary studies on the efficacy of oral doses of Ivermectin (0.05mg/Kg) for control of sea lice on Atlantic salmon and has been demonstrated to be effective in controlling all developmental stages of sea lice and reducing population of sea lice. Ivermectin 1% derived from avermectins, a family of highly active, broad spectrum antiparasitic agent isolated from fermentation of the naturally occurring soil organism Streptomyces avermitilis. Ivermectin is a member of the macrocydic lactones class of insecticides which act by binding to glutmate-gated chloride ion channel which occur in invertebrate nerve and muscle cells but not occur in mammals, this leads to an increase in the susceptibility of cell membrane to chloride ion with hyperpolarization of the nerve or muscle cell leading in paralysis and death of the parasite.

CONCLUSION

To control Caligus infestation in cultured Sea bass farms must be apply the management strategies such as the farm should be located in

which the water current is strong to flash away copepod stage; using wooden slats for trapping eggs of parasite; also, filtering of incoming water to remove larval stages of parasite and finally stocking clean fish and quarantining incoming fish with suitable treatment before stocking. For treatment of Caligus using in cultured Sea bass must be treated before stocking with Ivermectin 1% (lotion 1%) in a dose 6ml/L 600ppm for 5minutes gave effective treatment in elimination of caligus species.

REFERENCES

Abou El-Atta, M.E. and Walaa T. El-Ekiaby, 2012. Prevalence of bacterial infection associated with Caligus infestation in cultured *Mugil cephalus* with trials to control. Abbassa Int. J. Aqua., 5 (1): 415-440.

Abou EL-Atta, M. El Sayed, 2013. Some bacterial and fungal affections causing disease problems in cultured Sea bream *(Saprus aurata)* in Damietta Governorate and trials for control. Arabian Aquaculture Society, 8 (2): 357-372.

Amlacher, E, 1970. Text book of fish diseases. TFH Publication, New Jersey, U.S.A., 117-135.

Anwar, E.A; I. Abd El Nasser and A.S. Ali, 2010. Association of *Vibrio Species* with Disease Incidence in Some Cultured Fishes in the Kingdom of Saudi Arabia, World Applied Sciences J., 8 (5): 653-660.

APHA (American public Health Association), 1985. Standard Methods for the examination of water and waste water 16th edition. Washington, DC.

APHA, 2005. Standard methods for the examination of water and waste water, 21th edition, Washington, American Public Health Association.

Avci, H.; S. Birincioglu; E.T. Eprkmen and M. Dereli, 2013. Comparative histopathological and immuno-histochemical evaluation in juvenile Sea bass *(Dicentrachus labrax)* and Gilthead sea bream *(Sparus aurata)* naturally infected with *photobacterium damselae* subsp. Piscicido. Revue. Mid vet., 164, (2): 72 -79.

Badawy, G.A, 1994. Some studies on ectoparasite infecting marine fish in Egypt. Ph. D Thesis, parasitology department. Faculty of Veterinary Medicine, Zagazig University.

Badawy, G.A., 2001. Some studies on ectoparasites of some marine fish in Egypt. Suez Canal Vet. Medical J., IV (2): 417-435.

Ben-Kahla Nakbi. A.; K. Chaieb; A. Besbes; T. Zamantar and A. Bakhrouf, 2006**.** Virulence and entero bacterial repetitive intergenic consensus PCR of vibrio alginalyticus strains isolated from Tunision cultred gilthead sea bream and sea bass outbreaks. Vet. Microb., 117: 321-327.

Bergey, D.H, 1994. Bergey's manual of determinative bacteriology, ed. Buchanan, R.E. and Gibbons, N.E. 9th ed. Baltimore, Williams and Wilkins.

Boxshall, G.A. and S.H. Halsey, 2004. An introduction to copepod diversity. The Ray Society, London. 966 pp.

Cheong, L.; R. Chou; R. Singh and C.T. Mee, 1983. Singapore. In: Quarantine and Fish Diseases in south east Asia. Report of a work shop held in Jakarta. Indonesia 7-10 December 1982, UNDP/FAO. IDRC. 47-63.

Costello, M.J., 2009. How sea lice from salmon farms may cause wild salmonid declines in Europe and North America and be a threat to fishes elsewhere. Proc. Biol. Sci., 276 (1672), (3385-3394).

Costello, M.J., 2006. Ecology of sea lice parasitic on farmed and wild fish. Trends Parasitol., 22: 475-483.

Egidius, E, 1985. Salmon lice, *Lepeophtheirus salmonis*. J. Anim. Morphol, physiol., 26:1-4.

Eissa, I.A.M.; Maather El. Lamie and Mona Zakai, 2012. Studies on crustacean diseases of sea bass, *Morone Labrax*, in Suez canal, Ismaillia Governorate. Life science Journal, 9 (X): 512-518.

Enany, M.E.; H.M. Ibrahim; M.E. Abou El Atta and M.M. El Adawy, 2011. Bacteriological and Histopathological studies on some bacterial pathogens diseases in cultured *Mugil Capito* in Ismailia Governorate. SCVMJ., (1): 1-10.

Ho, J.S. and C.L. Lin, 2004. Sea Lice of Taiwan copepod: Siphonostomatoida: Caligidae. Sueichan Press, Taiwan.

Ho, J.S.; C.L. Lio and S.N. Chen, 2000. Species of *Caligus Müller*, 1785 (Copepoda: Caligidae) parasitic on marine fishes of Taiwan, 46 (3): 159-179.

Jale, K, and T. Gülsen, 2008. Marine Vibrios associated with diseased sea bass (*Dicentrarchus labrax*) in Turkey, 21(1): 66-76.

Johnson, S.C; J.W. Treasurer; S. Bravo; K. Nagasawa and Z. Kabata, 2004. A review of the impact of parasitic copepods on marine aquaculture. Zoological Studies, 43: 229-243.

Johnson, S.C. and L. Margolis, 1993. The efficacy of Ivermectin for the control of sea lice on sea farmed Atlantic salmon. Diseases of Aquatic organisms, 17: 107-112.

Kabata, Z., 1977. Parasitic Copepoda of British fishes. London: The Ray Society.

Kabata, Z., 1988. Copepoda and Branchiura. p. 3-127. *In* L. Margolis and Z. Kabata (eds.) Guide to parasites of fishes of Canada. Part II. Crustacea.. Can. Spec. Publ. Fish. Aquat. Sci., 101. 184pp.

Lester, R.J.G. and C.J. Hayward, 2006. Phylum Arthropoda, pp 466-565. In P.T.K., Woo. (ed.). Fish diseases and disorders Vol 1: Protozoan and Metazoan Infections. 2nd edition. CAB international, London.

Lin, C.L; J.S. Ho and S.N. Chen, 1994. Two species of Caligus (Copepoda, Caligidae) parasitic on black sea bream (*Acanthopagrus schlegeli*) cultured in Taiwan. Fish Pathology, 29: 253–264.

Lin, C.L.; J.S. Ho and S.N. Chen, 1997. Development of *Caligus multispinosus Shen*, a caligid copepod parasitic on the black sea bream (*Acanthopagrus schlegeli*) cultured in Taiwan. Journal of Natural History, 31: 1483–1500.

Lucky, Z, 1977. Methods for the diagnosis of fish diseases American Publishing Co., Pvt. Ltd., New Delhi, Bombay Calcutta and New York.

Maather, M.M. El-Lamie, 2007. Studies on the parasitic diseases in some marine fish. Ph. D. Thesis, Fac. Of Vet. Med. Dept. of fish Diseases and Mangement. Suez Canal University.

Marzouk, M.S.; M.I. Hanna and Amany M. Kenawy, 2009. Monitoring the cause of mortality in some marine Fishes in Matrouh Governorate, Egypt during the summer 2008. American Eurasian J. Agric. & Environ. Sci., 5 (2): 148-158.

Noga E.J., 2010. Fish disease: Diagnosis and treatment. Copyright Mosby-year Book, Watsworth Publishing, second edition, Co., U. S.A.

Noor El-Deen, A.I.E; Abeer E. Mahmoud and Azza H.M. Hassen, 2013. Field studies of caligus parasitic infections among cultured Sea bass *(Dicentarachus labrax)* and Mullet *(Mugil cephalus)* in marine fish farms with emphasis on treatment trials. Global Veterinaria, 11 (5): 511-520.

Nylund, A.; C. Wallace and T. Hovland, 1993. the possible role of lepeophtheirus salmon is (Kroyer) in the transmission of in factious salmon anemia, pp. 367-373. In G.A. Box shall and D. Defaya (eds). Pathogens of wild and farmed fish: sea lice, Ellis Horword , New York.

Ozak, A.A., 2006. Studies on the biology of parasitic copepod, Caligus minimus, Otto 1821 on Sea bass *(D. labrax L, 1758)*. Degree Diss., Universty of Cukurova Turkey.

Palmer. R.; H. Rodger; E. Drian; C.D. wyer; P.R. Smith, 1987. Preliminary trials on the efficacy of Ivermectin against parasitic copepods of Atlantic salmon. Bulletin of the European Association of fish pathologists, 7: 47-54.

Paperna, I., 1986. Parasitic infestation and diseases of fish in Africa. FAO, CIFA Technical paper, 51- 62.

Paperna, I. and P. Baudin Laurencin, 1979. Parasitic infections of sea bass, *Dicentrarchus labrax,* and gilt head sea bream *Sparus aurata*, in mariculture facilities in France. Aquaculture, 16: 173-175.

Papoutsoglou, S.; M.J. Costello; E. Stamou and G. Tziha, 1996. Enviromental conditions at sea cages and ectoparasites on farmed European sea bass *Dicentrarchus labrax(L),* and gilt head sea bream *Sparus aurata* L., at two farms in Greece. Aquaculture Res., 27: 25-34.

Pavoletti, E.; M.L. Fioravanti; M. Prearo and C. Ghittino, 1999. Osservazioni sulla Caligosi in spigole d, allevamento. Boll. Soc. Ital. Patol. Ittica, 11:2-9.

Pike A.W. and S.L. Wadsworth, 1999. Sea lice on salmonids: their biology and control. Advances in Parasitology, 44: 234-337.

Pujalte, M.J.; A. Sitja – Bobodilla; M.C. Macina; C. Bellock; P. Al varez-Pellitero; J. Perez – sanchez; F. Uruburu and E. Gàràỳ, 2003. virulence and molecular typing of *Vibrio harveyi* strains isolated from cultured dentex gilthead sea bream and European sea bass. Syst. Appl. Microbiol., 26: 284-292.

Ragias V.; D. Tonis and F. Athanassopoulou, 2004. Incidence of an intense *Caligus minimus* Otto 1821, *C. pageti* Russel, 1925, *C. mugilis* Brian, 1935 and *C. apodus* Brian, 1924 infection in lagoon cultured sea bass *(Dicentrarchus labrax L.)* in Greece. Aquaculture, 242: 727-733.

Roberts, R.J., 2001. Fish pathology 3rd ed. WB. Saunders, Philadiphia, PA. U.S.A., 472 pp.

Schäperclaus, W.; H. Kulow and K. Schreckenbach, 1992. Fish diseases, Vol. I. A.A. Balkema /Rotterdam, septicemia of fish, Fish disease leaflet, 68 (1- 24).

Smith, P.R.; M. Maloney; A. Mc Elliott; S. Clarke; R. Palmer; J. O'Kelly and J. O'Brien, 1993. The efficacy of oral Ivermectin in the control of sea lice infections of farmed Atlantic salmon. In: Box shall, G, A. and Def aye D (eds) pathogens of wild and farmed fish: sea lice. Ellis Horwood, chichester, UK, PP. 296 -307.

Sterud, E., 2002. Parasites of wild sea bass *(D. Labrax)* from Norway, Diseases of Aquatic Organisms, 48: 209-212.

Taghrid M.N. Abd El-Hakim, 2011**.** Polymerase Chain Reaction for diagnosis of some fish bacterial pathogens. M. V. sc thesis bacteriology. Department of bacteriology. Mycology and immunology, Veterinary Medicine, Zagazig University.

Tansel, T. Tanrikul and Faith Percin, 2012. Ecto parasitic sea lice, *Caligus minimus* (Otto 1821, cope poda: Caligidae) on Brawn wrasse, *Labrus merula L.*, In Izmir Bay, Aegean Sea. Italian Journal of animal science, 11. 38: 208-210.

Timi, J.T. and A.L. Lanfranchi, 2006. Size relationships between the parasitic copepod, *Lernanthropus cynoscicola*, and its fish host, *Cynoscion guatucupa.* Parasitology, 132 (Pt 2): (13-207).

Woo, P.T.K. and D.W. Bruno, 1999. Fish Diseases and Disorders. Vol. 3. Viral, Bacterial and Fungal infections. CAB International, Wallingford, UK, 874pp.

Woo, P.T.K., 2006. Fish Diseases and Disorders, Volume 1: Protozoan and Metazoan Infections, Second Edition, Library of Congress Cataloging-in-Publication Data, P. 518.

Woo, P.T.K; D.W. Bruno and L.H.S. Lim, 2002. Infectious diseases of warm water Fish in marine and brackish waters. CAB international 2002. Diseases or disorders of finfish in cage, 217-219.

Yambot, A.V. and E.A. Lopez, 1997. Gill parasite *Lambroglena monody*, Capart, infecting the Nile tilapia, *Oreochromis niloticus* L., cultured in philipines. Proceeding of the 3rd Symposium on Diseases in Asian Aquaculture, Bangkok, Thailand, 175-177.

Zorrilla. I.; M. A. Morinigo; D. Castro; M.C. Balbona and J.J. Borrego, 2003b. Intraspecific characterization of *Vibrio alginolyticus*

isolates recovered from cultured fish in spain. J, Appl. Microbiol., 95: 1106-1116.

العدوى بقمل السمك ودورها فى تغزير العدوى البكتيرية فى أسماك القاروص المستزرعة فى محافظة دمياط

محمد السيد أبوالعطا

قسم بحوث صحة الاسماك- المعمل المركزى لبحوث الثروة السمكية (العباسة) مركز البحوث الزراعية- مصر.

الملخـــص العربـــى

بفحص عدد ١٠٠ سمكة مريضة ظاهريا من اسماك القاروص تم تجميعها من منطقة مثلث الديبة محافظة دمياط حيث تم فحصها ظاهريا وداخليا وصورة الدم للاسماك المصابة والسليمة و بكتريولوجيا و طفيليا وباثولوجيا. وكذلك تم قياس بعض الصفات الفيزيائية والكيميائية للمياة أسفر الفحص الاكلينكي للأسماك المصابة إنها كانت تعانى من رفض الغذاء والتوتر وزيادة كمية المخاط على الجسم و أعراض عصبية حيث كانت الأسماك المصابة بقمل السمك تحك جسمها بالمواد الصلبة داخل الحوض فى محاولة للتخلص من قمل السمك مع وجود عتامة على الجسم والقفز فوق سطح الماء والتنفس بصعوبة قريبا من السطح إنتشار البقع النزيفية والتقرحات الجلدية على معظم اجزاء الجسم كما أظهرت النتائج ان الأسماك المصابة تتزاحم حول مدخل المياة وأظهرت الصفة التشريحية وجود اعداد كبيرة من قمل السمك على سطح الجسم وفى تجويف الفم وعلى الخياشيم وكانت الخياشيم فى معظم الأسماك باهتة اللون و كذلك الكبد والبعض الاخر وجد احتقان بالأعضاء الداخلية. اوضحت نتائج تحليل صورة الدم للاسماك المصابة النقص فى حجم كرات الدم (PCV) والهيموجلوبين والبروتين الكلى والكالسيوم وزيادة نسبة السكر وكذلك انزيمات وظائف الكبد والكلى مقارنة بالاسماك السليمة. تبين من الفحص البكتريولوجى تم عزل ميكروب الفيبرو الجينولتكس بنسبة ٣٥% من الأسماك المصابة بقمل السمك بنسبة عالية من التقرحات الجلدية و الخياشيم، الكبد والكلى على التوالى وبنسبة اقل من الطحال والدم، وقد وجد ان هذا الميكروب حساس للسيبروفلوكساسين

والفلوروفنيكولزوانروفلوكساسين والنالديكسك اسيد وأثبتت نتائج اختبار الضراوة ان ميكروب الفيبرو الجينولتكس يحدث نفوق بنسبة ١٠٠% عند الحقن البريتونى. طفيليا تم عزل نوعين من القشريات الطفيلية (كاليجس مينيمص) و(كاليجس كارينجص) كما تمت مناقشة ووصف التركيب المورفولوجى للطفيليين وكانت النسبة الكلية للاصابة ١٠٠% حيث كان متوسط الأصابة ٢٥ طفيل للسمكة. وقد تم دراسة التغيرات الهستوباثولوجية التى حدثت فى الجلد والخياشيم للأسماك المصابة والكبد والكلى والطحال. واوضحت محاولات العلاج ان استخدام الجرعة ايفرميكتين ١% بمعدل ٦ ملي/ لتر ماء كحمام مائى لمدة ٥ دقائق فعالة فى التخلص من قمل السمك (الاطوار االبالغة والغير بالغة) فى المياة المالحة دون التأثير على الحالة الصحية للأسماك المعالجة و لذلك يوصى باستخدام ايفرميكتين ١% غسول ١% فى علاج الطفيليات القشرية وخاصة قمل السمك.