Abbassa Int. J. Aqua., V0l.14 No.(1) 2021. **43 - 68**

IMMUNOHISTOCHEMICAL STUDY ON THE EFFECT OF CHROMIUM CHLORIDE HEXAHYDRATE SUPPLEMENTATION ON COMMON CARP (*Cyprinus carpio L.*) FINGERLINGS CHALLENGED WITH *Aeromonas veronii* AND COLD STRESS

Ahmed Ali Ahmed

Department of Fish Health and Management, Central Laboratory for Aquaculture Research, Agriculture Research Center, Egypt.

Received 26 /1 /2021 *Accepted 23 /2 /2021*

ABSTRACT

Cold stress is a main threat on fish in both nature and aquaculture. It can induce oxidative stress in various fish. While the exact role of oxidative stress in cold-caused mortality is still unknown. This study showed that cold exposure induced oxidative stress in common carp fingerlings liver and intestine, which may lead to mortality. The aim of this study was to determine the antioxidant and anti-apoptotic effects of chromium chloride on cold tolerance in common carp fingerlings via assessment of immunohistochemical heme oxygenase 1, caspase 3 expression in liver and intestine. In two months' feeding trial, fish fed with experimental diets containing chromium chloride Hexahydrate (0, 0.3, 0.5 and 0.6 mg kg-1) during winter. In the current study, the common carp fingerlings which were fed with chromium chloride 0.3 mg kg-1(2nd group) showed weak caspase 3 expression and strong heme oxygenase 1 expression in both liver and intestine with lower cold-caused oxidative stress and tissues damage, and showed higher cold tolerance. Evaluation of growth performance revealed improved performance parameters than other groups. These results confirmed possible antioxidant, anti-apoptotic and beneficial effects of chromium chloride on common carp fingerlings in a dose dependent manner. Also, the lowest mortality rate detected in 2nd group insists on antioxidant value of chromium chloride hexahydrate. While, the 4th group (0.6 mg kg-1) showed strong caspase 3 expression and weak heme oxygenase 1 expression in both liver and intestine. The present study concluded that reduction of oxidative stress will increase cold tolerance and challenge the infections of *Aeromonas veronii* in common carp fingerlings fish.

Keywords: common carp, fingerlings, cold stress, Chromium Chloride Hexahydrate.

INTRODUCTION

Cold stress is a main threat to fish in both aquaculture and nature, and can produce oxidative stress in various fish (Lu *et al.*, 2019a). In a cold atmosphere, fish decrease or stop feeding, decrease biochemical activities such as nutrient conversion from carbohydrates to lipids, lipid catabolism, autophagy and the inhibition of mitochondrial fatty acid β-oxidation by which energy kept to preserve a relatively stable body temperature and metabolic homeostasis (Lu *et al.*, 2019b). Common carp, (*Cyprinus Carpio L.*,) is native to Central Asia and Eastern Europe and spread in freshwater habitats (Takahara *et al.*, 2011). common carp *Cyprinus carpio* is a worldwide distributed freshwater species with excessive commercial import since its aquaculture production exceeded 4 million tons in 2014. Considering the production numbers and their importance in the aquaculture, This specie is of main interest and major consumers of feeds (Kriton *et al.*, 2018). Carp processing produces an excessive amount of by-products used to recover collagen, which improve protein hydrolysates with antioxidant properties that can support the utilization of by-products from this fish species (Tkaczewska *et al.*, 2018). Numerous studies surveyed the common carp as an experimental model to explore fish cold tolerance-related issues (Hirayama *et al.*, 1998; Sun and Liang, 2004 and Liang *et al.*, 2015). Obviously, increased common carp mortality rate documented in cold stress (Poledník *et al.*, 2008 and Liang *et al.*, 2015). Oxidative stress defined an imbalance between oxidants and antioxidants in favor of the oxidants, potentially leading to damage. Free radicals contribute to the etiology of several chronic disorders and complications. Antioxidants prevent free radical-induced tissue damage by avoiding the establishment of radicals, by scavenging them or by encouraging their decomposition. Anti-oxidative peptides consequent from foods are being safe compounds of low molecular weight, low cost, chief activity and easily absorbable (Tkaczewska *et al.*, 2019). Heme oxygenase-1 (HO-1), an enzyme that catalyzes the degradation of heme to produce carbon monoxide (CO), biliverdin and ferrous iron (Fe2+), exerts anti-oxidant, anti-inflammatory and antiapoptotic properties

and similarly acting a significant role in host defense against microbial infection. HO-1 displays important antiviral properties against a growing variety of human viruses, (Li *et al.*, 2018 and Tseng *et al.*, 2016). Apoptosis can arise from immune reactions and toxic chemicals, and there are two types of apoptosis pathways, such as the intrinsic mitochondrial pathway and the extrinsic death receptor pathway (Elmore, 2007). It is modulated by the caspase family of aspartic acid-directed cysteine proteases (González *et al.*, 2010). Caspase-3 gene sequences have been identified in common carp (Gao *et al.*, 2013 and Özdemir *et al.*, 2018). Thus, the caspase-3 gene sequence makes it easier to investigate the effects of pesticide toxication on the apoptosis in common carp. Chromium (Cr) is a metallic element that exists in many chemical valence states, but the most stable forms occurring in the environment are the 0 valence state (metal and alloys), trivalent chromium [Cr (III)], and hexavalent chromium [Cr (VI)] (Vlizlo *et al.*, 2014). Many authors pay attention to the potential danger of chromium deficiency, which can cause intolerance and inability to use glucose for energy (diabetic and diabetic-like states), cardiovascular disease (increased aortic plaque formation and disturbance of hematological parameters), elevated blood lipids and high free fatty acid levels, small respiratory quotient, abnormalities of nitrogen metabolism, impaired growth, and decreased fertility and longevity in both humans and animals (Pechova and Pavlata, 2007). Previously, it was showed a weakening of natural resistance factors, which takes place in animals fed a chromium-deficient diet. It is caused by deterioration of membrane cells receptors activation to insulin, which becomes less supplied with energy and functionally weaker (Chen *et al.*, 2009). Several studies have established beneficial effects of supplemental trivalent Cr in subjects with reduced insulin sensitivity with no documented signs of toxicity. However, recent studies have questioned the safety of supplemental trivalent Cr complexes. The Chromium chloride Hexahydrate (CrCl3; 6H2O) when present in excess amount induces toxic effects in the cells like genotoxicity and oxidative damage (Lushchak et al., 2009 and Guo *et al.*, 2020). Earlier, many researches established the toxic effect of higher doses of hexavalent chromium chloride. Administration of 5%

and 10% of 96 hr-LC_{50} (85.7 mg/L) of aqueous Cr (VI) in a continuous flow through system for 28 days promoted genotoxicity and lipid peroxidation in the liver and kidney cells of goldfish (Velma and Tchounwou, 2013). Because Chromium chloride Hexahydrate (CrCl3; 6H2O) bioactivity is still fairly unknown and little discussed in fish.

This study examined the influence of hexahydrate trivalant chromium chloride supplementation on hepatic and intestinal antioxidant, apoptosis status and growth performance in common carp fingerlings challenged with *Aeromonas veronii* and cold stress in a dose dependent manner.

MATERIALS AND METHODS

Fish:

In this experiment, apparently healthy common carp fingerlings was collected from Abbassa Fish hatchery, Central Laboratory for Aquaculture Research, Abbassa, Abo-Hammad, Sharqia, Egypt, and kept in fiberglass tank for two weeks for adaptation. Two hundred and forty common carp fingerlings (2±0.05g) were stocked in 12 glass aquaria (80×40×30 cm) supplied with aerated and de-chlorinated tap water. Glass aquaria assigned to four treatments with three replicates at a rate of 20 fish per glass aquaria. The oxygen was adjusted for continuous aeration by using electrical air pumping compressors. Two-third of the aquarium water was siphon daily to maintain water quality. Water temperature during January and February 17±4 °c The fish were fed twice daily. The amount of feed offered to fish (5%) of live body weight. Fish were weighed individually at the beginning of the experiment and weekly during the experimental period to adjust the feeding level for the subsequent week.

Diet preparation and feeding trails:

Four experimental diets formulated to satisfy the nutrient requirements of common carp according to NRC (NRC, 2011). Chromium chloride Hexahydrate (CrCl3; 6H2O) obtained from Oxford Laboratory Co., India. The

formulated diets were supplemented with 0% (basal that contained 30.8% crude protein and 7.1% crude lipid) (Table 1). Four diets were formulated to contain (0, 0.3, 0.5 and 0.6 mg kg^{-1}) of Chromium Chloride Hexahydrate (Asad *et al.*, 2019). All ingredients were mixed with oil and then adding water until stiff dough resulted. Each diet was then extruded through an extruder. The resulting strands were shadow-dried, broken up, sieved into pellets, and stored in plastic bags until used. The feeding trial lasted for 2 months from (1st January to 1st, march).

Table 1. Formulation and composition of the basal diet.

Ingredients	Weight/g
Ground yellow corn	203
Soybean meal (44% CP)	430
Wheat bran	155
Fish meal (72% CP)	104
Corn oil	15
Cod fish oil	23
Mineral premix	10
Vitamin premix	20
Starch	40
Total	1000
chemical analysis (g/kg)	
Crude protein	30.8
Dry matter	92.3
Total ash	5.2
Crude fiber	7.2
Crude lipid	7.1

Growth performance:

Individual weights of fish were measured at the start, after one month and at end of the experiment by using digital balance. Fish weight was measured to calculate growth performance using the following formula:

weight gain (WG) = (final body weight–initial body weight)

Increase in length (Cm) = Final length (Cm)- Initial length (Cm) according to (De Silva and Anderson, 1995)

Challenge test:

Pathogenic *Aeromonas veronii* bacterial strain was previously isolated and identified in Department of Fish Health and Management, Central Laboratory for Aquaculture Research, as was used for challenge test. After the completion of the feeding trial of 2 months, 5 fish per replicate (n=15 fish/group) were injected intraperitoneally with 0.1 ml of *A. veronii* suspension with bacterial cell concentration of 1.5×10^7 CFU. Fish mortality was monitored in all the experimental groups for (15 days) post-challenge period (Ruangroupan *et al.*, 1986).

Handling of tissue samples:

At the end of exprement (2 months) liver and intestine were dissected for examination and preparation for histological and immunohistochemical screening.

Histopathological examination:

Liver and intestine specimens immersed in 10% neutral buffered formalin, dehydrated in ascending concentrations of ethyl alcohol (70–100%), immersed in xylene, and processed formalin fixed paraffin embedded (FFPE) sections, and finally cut into 4 µm sections using a microtome. Further, one FFPE specimen was stained with hematoxylin and eosin (H&E) for microscopic examination and imaged each section using a light microscope (Axio Imager.A2, ZEISS).

Immunohistochemistry (IHC) examination:

IHC protocol was implemented following the method of (Williams *et al.*, 2015). Formalin fixed paraffin-embedded specimens were cut into 4-µm sections. After de-paraffinization, sections were heated in Tris/HCL buffer (pH 9.0) for 20 min at room temperature for antigen retrieval. After that, sections were incubated with 0.3% H2O2 in absolute methanol for 30 minutes. Then, incubation with primary antibody against caspase-3 (Cataloge# GTX30246, GeneTex Inc.), heme Oxygenase 1 (Cataloge# A19062, ABclonal), and

secondary antibodies as biotinylated polyvalent (Thermo Scientific Co., UK, Catalog# 32230) were performed. All slides are lightly counter-stained with hematoxylin for 30 seconds prior to dehydration and mounting. Each section was captured using a light microscope (Axio Imager.A2, ZEISS). Positively stained area percentage was quantified via ImageJ software per slide after light background subtraction.

Immunohistochemical scoring:

Cells with cytoplasmic reaction to antibodies were positive. Staining of cells was taken as the positive internal control. Semi-quantitative analysis of stained tissue sections was performed through changed Allred scoring system guidelines. The staining intensity of positivity in the cytoplasm was scored as: 1-weak; 2-medium; and 3-strong (Ilic *et al.*, 2019).

Statistical analysis:

The normality of obtained data confirmed and then significant difference ($P < 0.05$) among treatments was determined by one-way ANOVA followed by Duncan Multiple Rang Test (post hoc test). Data were expressed as the mean ±SE. All statistical analysis was done by SPSS 16.0 (SPSS Inc., Chicago, IL, USA). (Dytham, 2011)

RESULTS

Clinical investigation:

Fish behavior, feed intake, feeding time, acceptability of feed were good. fish behavior was normal in 2nd and lower limit in 4th group. Control 1st and 4th group were inactive. Refused food intake, loss of escape reflex, loss of balance, sluggish swimming and swim near to the water surface was more obvious in 4th group because of cold stress. It was particularly noted that the fish in the 1st and 4th groups fed slowly. Whereas fish in 2nd group was the best fed actively throughout the experiment.

Growth performance:

Table 2 revealed that Chromium Chloride Hexahydrate administration at doses of 0.3, 0.5 mg kg-1 in 2nd and 3rd groups respectively significantly ($P < 0.05$) increased weight gain and length increase comparing to control 1st group. Weight gain and length increase showed higher values in the 2nd group than 3rd group. On contrary, 4th group exhibited lower value comparing to other experimental groups after 1st and 2nd months.

Histopathological changes of common carp fingerlings:

Intestine of 2nd group fed of (0.3 mg kg-1) Chromium Chloride Hexahydrate show normal histological architecture (normal tunica muscularis, normal lamina propria and intact intestinal epithelium) with increased numbers of goblet cells. The 2nd group reveals the highest folding of intestinal villi, a marked increase of villi folding, length and numbers enhance absorptive capacity as compared to the 1st and 4th groups that revealed marked entire villi shortening and blunting than other groups. 1st group (control) appeared with low folding of intestinal villi, degeneration and sloughing of the apical part of the intestinal villi epithelium in the intestinal lumen with low numbers of goblet cells. 4th group fed of (0.6 mg kg-1) of Chromium Chloride Hexahydrate shows no folding and complete sloughing of intestinal villi, with degeneration and desquamation of the intestinal villi epithelium in the intestinal lumen and goblet cells appeared with tiny numbers, because of exposure of cold stress and high dose of Chromium Chloride hexahydrate figure (1).

Liver of 1st and 4th group showing elongated central vein and engorged with blood. Also, liver shows degenerative and necrotic changes. Hepatocytes show necrotic changes with the pyknotic nucleus. Liver of 2nd and 3rd group viewing nearly normal liver architecture with normal hepatocyte and normal hepatic sinusoid Figure (2).

Immunohistochemical heme Oxygenase 1 and caspase 3 expression in common carp fingerlings:

Area percents of immunohistochemical caspase 3 expression with different doses of chromium chloride in intestinal villi were small area 11.712% in a 2nd group representative low apoptotic changes in compared with 39.423% in the 4th group which reveal increasing of apoptosis and necrosis (Table 3). In contrast, area percent of immunohistochemical heme Oxygenase 1 expression with different doses of chromium chloride in intestinal villi were large area 47.269% 2nd group representing the antioxidant effects in compared with other groups (Table 4). Area percent of immunohistochemical caspase 3 expression with different doses of chromium chloride in liver were 22.113% in a 2nd group demonstrative low apoptotic changes in compared with 51.200% 4th group which reveal increasing of apoptosis and necrosis (Table 5). while, Area percent of immunohistochemical heme Oxygenase 1 expression with different doses of chromium chloride in liver were large area 28.964% 2nd group denoting the antioxidant effects in compared with other groups (Table 6). IHC revealed 1st group delineated moderate caspase 3 expression in most cells (A); 2nd group showed weak caspase 3 expression (B); 3rd group outlined moderate caspase 3 expression in few cells (C) 4th group exhibited strong caspase 3 expression (D) in intestine (Figure 1) in liver (Figure 3). Concerning heme oxygenase 1, IHC showed 1st group delineated moderate heme oxygenase 1 expression in few cells (A); 2nd group showed strong heme oxygenase 1 expression (B); 3rd group outlined moderate heme oxygenase 1 expression in most cells (C); 4th group exhibited weak heme oxygenase 1 expression (D) in intestine (Figure 2), and in liver (Figure 4).

Challenge test:

It was observed that the highest mortality rate after intraperitoneally injection of 0.1 ml of *A. veronii* suspension with bacterial cell concentration of 1.5×10^{7} CFU in 4th group was 86.6% expected to the oxidative stress and apoptosis induced from a high dose of chromium chloride and cold stress, while the lowest mortality rate detected in 2nd was 40% insist on antioxidant

value of chromium chloride hexahydrate administration in levels (0.3mg kg-1) (Table 7).

DISCUSSION

In the present study, chromium chloride fed (0.3 mg kg-1) significantly increased body weight and length gain that came in consistent with the results of (Ghazi *et al.*, 2012 and Samanta *et al.*, 2008). Those clarified that Cr administration significantly improved the growth performance variables by increased body weight gain, feed intake, improved feed conversion ratio, and decreased mortality rate in poultry. This improvement in growth performance might be because of the mediated activity Cr by the anabolic action of insulin (Lukaski, 2019). Also, Previous studies have identified Cr as a Glucose Tolerance Factor (GTF) and its absence could cause hypercholesterolemia and retarded growth (Tang *et al.*, 2015). Beneficial effects of Cr on productive, physiological and traits reproductive performance had been stated either under low or high temperatures (Farag *et al.*, 2017). Histopathological study showed that intestine of 2nd group fed (0.3 mg kg-1) Chromium Chloride Hexahydrate show normal histological architecture (normal tunica muscularis, normal lamina propria and intact intestinal epithelium) with increased numbers of goblet cells. The marked increase in villi folding, length and numbers enhance absorptive capacity as compared to the other groups. These finding agreed with (Moeini *et al.*, 2011) who noted that chromium chloride improved body weight because of their increased absorption and bioavailability. Alternatively, 4th group fed (0.6 mg kg-1) of Chromium Chloride Hexahydrate shows no folding and complete sloughing of intestinal villi, with degeneration and desquamation of the intestinal villi epithelium in the intestinal lumen and goblet cells appeared with tiny numbers, because of exposure of cold stress and high dose of Chromium Chloride Hexahydrate Figure (1) these finding explain the low weight gain and length gain in compared with 1st group. Chromium is employed in food, feed and pharmaceutical purposes due to its role in nutrient metabolism such as carbohydrates, fats , proteins, nucleic acids and amino

acids (Khan *et al.*, 2014), furthermore, chromium deficiency can make severe atherosclerosis and interrupt blood lipid levels while Cr supplementation can decrease cholesterol content, improve lipid metabolism, and increase the amount of triacylglycerols, which are less exposed to lipid peroxidation because of their chemical structure (Vincent, 2001). In this study, administration at lower doses of 0.3, mg kg-1 upregulated regulated heme oxygenase 1 expression in line with down regulated caspase 3 expression. These may be attributed to its antioxidant potentials agreeing with **(**Cheng *et al*. 2004; Iskra and Yanovych 2013 and Vlizlo *et al*. 2014). These may be attributed to participation in redox reactions that are crucial for normal functioning and integrity of cells and tissues in the organism. It is known that the reaction to stress generates reactive oxygen forms, including superoxide anion radicals (O2-), hydroxyl radicals (HO-), and hydrogen peroxide (H2O2), which cause lipid peroxidation, especially in membranes, and can cause tissue damage (Chen *et al.*, 2009). Superoxide (O−2), one of the parental forms of intracellular ROS, is a very reactive molecule, but it can be transformed to H2O2 by superoxide dismutase (SOD) and then to oxygen and water by several enzymes including catalase (CAT) and glutathione reductase (GR) (Kumari *et al.*, 2014). Therefore, examining the change in antioxidant such as heme oxygenase-1 shall be a proper method of representing oxidative stress, and other biomarkers could be the viable tools in aquatic toxicological research. Some reports have specified the effect of food supplementation with chromium (CrCl3 · 6H2O) on intensity of peroxide processes and activity of antioxidant enzymes has been investigated in some rat tissues. Food supplementation with 200 µg/kg CrCl3 · 6H2O for 30 days resulted in the increase of tissue chromium and increased glutathione peroxidase, glutathione reductase, and catalase activity (Iskra and Yanovych, 2013). Besides, chromium supplementation for 6 months with 1000 µg/day of Cr (as Cr yeast) increased total anti-oxidative status (TAS) in type 2 diabetes (Cheng *et al.*, 2004). It was detected that the lowest mortality rate detected in 2nd was 40% insist on antioxidant value of chromium chloride hexahydrate administration in levels (0.3mg kg-1) in compared to other groups (Table 7). These results agreed with

(Vlizlo *et al.*, 2014) who confirmed that trivalent chromium ions CrCl3 supplementation decreased lipid peroxidation, increased catalase, glutathione peroxidase, glutathione reductase, and reduced glutathione (GSH) in erythrocytes, lysozyme and bactericidal activities of blood serum that explain the lower mortality rate. In contrast, it was studied that the highest mortality rate after intraperitoneally injection of 0.1 ml of *A. veronii* suspension with bacterial cell concentration of 1.5×10^{7} CFU in 4th group (0.6 mg kg-1) was 86.6% expected to the oxidative stress and apoptosis induced from a high dose of chromium chloride and cold stress. This finding is matched with (Roberts *et al.*, 2004) who remark that This oxidative stress may outstanding to either directly induce an increased construction of reactive oxygen species (ROS) by catalyzing a Fenton-like redox cycling mechanism or indirectly promote oxidative stress by interacting with mitochondria. Reactive oxygen species can attack multiple cellular constituents contain protein, nucleic acids, and lipids, leading to disruption of cellular function and integrity favoring apoptosis. Additional studies have confirmed that excessive ROS generation leads to apoptosis (Köktürk *et al.*, 2020). Apoptosis involved intrinsic (mitochondrial), and extrinsic (death ligand) pathways. During mitochondrial pathway, there are stimuli to reduce BCL2 resulting in cytochrome c- altered mitochondrial permeability and released into the cytoplasm to activate activation of apoptosis related factor 1 and caspase-9, then activate procaspase-3 and subsequently caspase-3 activation induced DNA fragmentation, and chromatin condensation. BCL-2 suppresses apoptosis by inhibiting the release of mitochondrial cytochrome c into the cytoplasm through maintaining mitochondrial permeability and membrane barrier stabilization, and impeding caspase stimulation (Suganya *et al.*, 2019). Concerning death ligand pathway, TNF-α interacted via TNFR1 and TNFR2 receptors resulting in caspase-3 activation (Wajant and Siegmund, 2019).On contrary higher dose 0.6 mg kg-1 revealed adverse effects on growth performance, and induced- oxidative stress and apoptosis that agreed with (Lushchak et al., 2009, Guo et al., 2020, Hininger *et*

al., 2007). These confirmed with our findings, such as upregulation of caspase 3 expression in line with downregulation of heme oxygenase 1.

CONCLUSION

The current study could be concluded with the Safety, nutritional and antioxidant value of chromium chloride hexahydrate administration in fish diet at the tested level (0.3 mg kg-1). On contrary, higher dose 0.6 mg kg-1 revealed adverse effects on growth performance, and induced- oxidative stress and apoptosis in common carp fingerlings challenged with *A. veronii* and cold stress after two months feeding.

Table 2. Growth performance of common carp fingerlings**.**

	1st	2nd	3rd	4th	1st	2nd	3rd	4th
	After 1 month				After 2months			
Initial weight (g/fish)	2± 0.05^{a}	2± 0.05 ^{a}	2± 0.05 ^{a}	2± 0.05 ^{a}	2± 0.05 ^{a}	2± 0.05 ^{a}	2± 0.05 ^{a}	2± 0.05 ^{a}
Final Weight (g/fish)	5± 0.17^{c}	7± 0.12^{a}	6± 0.17^{b}	4.5± 0.17^{c}	10± 0.29^{c}	14.6± 0.35^{a}	11± 0.58^{b}	9± 0.12^{c}
weight gain (g)	3± 0.12^{c}	5± 0.06^{a}	4± 0.12^{b}	2.5± 0.20^{d}	8± 0.23^{b}	12.6± 0.29^{a}	8.33± 0.34^{b}	7± 0.06^{c}
Initial length (cm)	3± 0.06 ^{a}	3± 0.06 ^{a}	3± 0.06 ^{a}	3± 0.06 ^{a}	3± 0.06 ^{a}	3± 0.06 ^{a}	3± 0.06 ^{a}	3± 0.06 ^{a}
Final length (cm)	6± 0.23^{c}	8± 0.12^{a}	7± 0.29^{b}	6± 0.12^{c}	9± 0.17^{b}	9.5± 0.29^{ab}	10± 0.35^{a}	8± 0.17^{c}
Length Increase (cm)	3± 0.17^{c}	5± 0.06^{a}	4± 0.23^{b}	3± 0.06^{c}	6± 0.12^{b}	6.5± 0.23^{ab}	7± 0.29^{a}	5± 0.12^{c}

Values are means ± SE, Means carrying different superscripts considered significant ($P < 0.05$).

Table 3. Area percent of immunohistochemical caspase 3 expression in common carp fingerlings intestinal villus**.**

Groups	Total areas	Specific area of caspase-3 reaction	Area percent%
1st group	9648479.452	3675952.249	33.759
2nd group	10383410.12	1216051.803	11.712
3rd group	10217584.88	2078587.067	20.343
4th group	10988881.81	4332195.101	39.423

Table 4. Area percent of immunohistochemical heme Oxygenase 1 expression in common carp fingerlings intestinal villus**.**

Groups	Total areas	Specific area of heme Oxygenase 1 expression	Area percent%
1ST group	2415457.340	237678.347	9.839
2nd group	2237594.836	1057680.24	47.269
3rd Group	2254443.944	743405.166	32.975
4th group	1911095.528	122169.540	6.393

Table 5. Area percent of immunohistochemical caspase 3 expression in common carp fingerlings liver**.**

Groups	Total areas	Specific area of caspase-3 reaction	Area percent%
1ST group	1489267.080	709722	47.655
2nd group	685648.800	151624.080	22.113
3rd Group	1485352.080	372639.600	25.087
4th group	1603193.040	820848.600	51.200

Table 6. Area percent of immunohistochemical heme Oxygenase 1 expression in common carp fingerlings liver**.**

Groups	Total areas	Specific area of heme Oxygenase 1 expression	Area percent%
1ST group	670521.146	115608.004	17.242
2nd group	676953.683	196073.637	28.964
3rd Group	687614.772	139134.167	20.234
4th group	698175.601	73667.232	10.551

Table 7. Mortality rates among the common carp fingerlings challenged with *A. veronii*.

Groups	Fish No	Dead	Percent%
1ST group (control)	15	12	80
2nd group	15	6	40
3rd Group	15	8	53.3
4th group	15	13	86.6

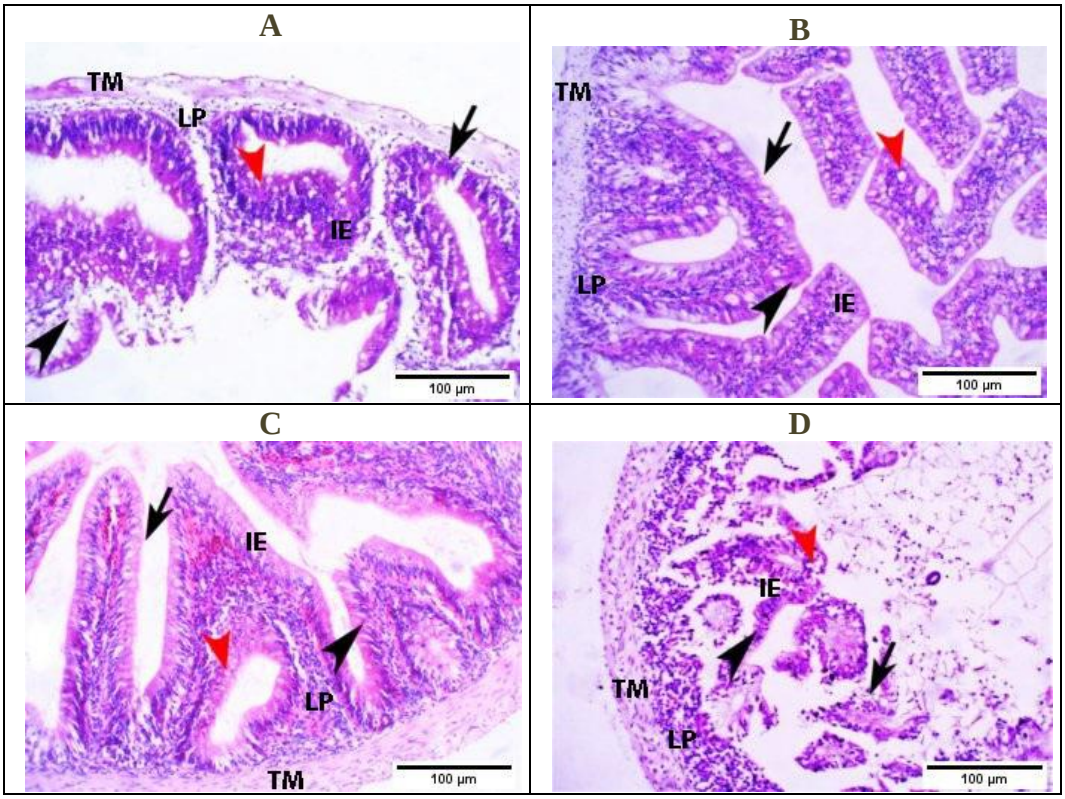

Figure 1. Graphical photomicrographs of intestinal histopathological sections in common carp fingerling.

(A): 1st group arrow shows low folding of intestinal villi while (black arrowhead) shows degeneration and sloughing of the apical part of the intestinal villi epithelium in the intestinal lumen and (red arrowhead) shows goblet cells with low numbers (B): 2nd group shows normal histological

architecture, normal tunica muscularis (TM), normal lamina propria (LP) and intact intestinal epithelial cells (IE). arrow shows high folding of intestinal villi, while (red arrowhead) shows goblet cells with increased numbers, (black arrowhead) show normal intestinal epithelial cells; (C): 3rd group: arrow shows normal intestinal villi with moderate increase in folding, while (red arrowhead) shows goblet cell with increased numbers and (black arrowhead) shows normal and intact epithelial cells; (D): 4th group arrow shows no folding and sloughing of intestinal villi, while (black arrowhead) shows degeneration and desquamation of the intestinal villi epithelium in the intestinal lumen and (red arrowhead) shows goblet cells with tiny numbers. Stain H&E. Bar = 100 µm.

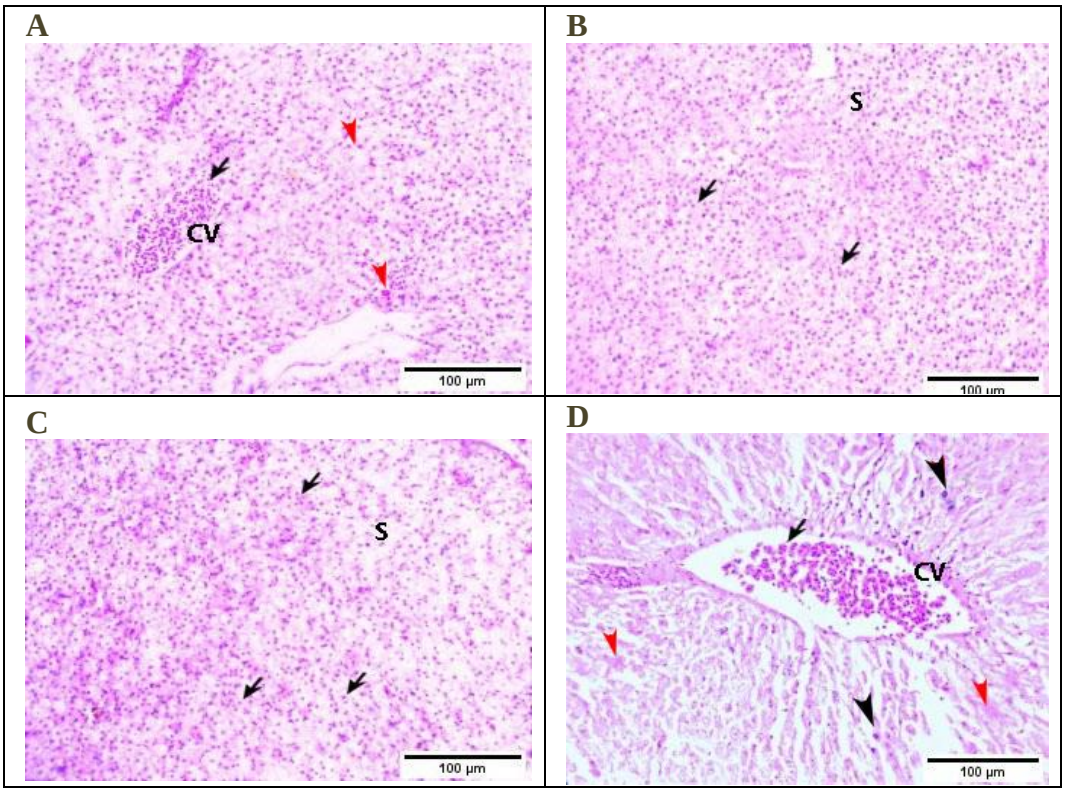

Figure 2. Graphical photomicrographs of liver histopathological sections in common carp fingerling.

(A): 1st group showing central vein (CV) elongated and engorged with blood (arrow), while (Red arrow head) showing necrotic changes in

hepatocytes with pyknotic nucleus; (B) 2nd group and (C) 3rd group: showing nearly normal liver architecture with normal hepatocyte (arrow) and normal hepatic sinusoid (S); (D) 4th group showing central vein (CV) elongated and engorged with blood (arrow), while (black arrowhead) showing necrotic changes in hepatocytes with pyknotic nucleus and (red arrowhead) showing hepatic necrosis. Stain H&E. Bar = 100 µm.

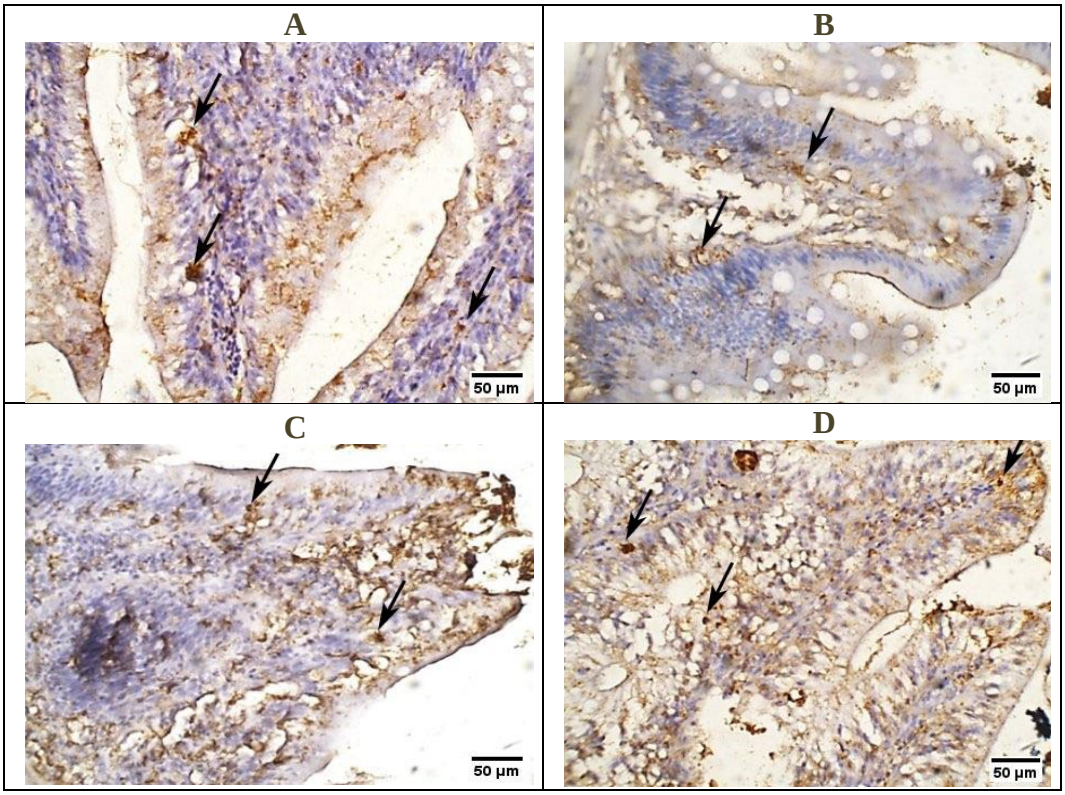

Figure 3. Graphical photomicrographs of immunohistochemical caspase 3 expression in common carp fingerlings intestinal villi.

(A): 1st group arrow delineated moderate caspase 3 expression in most cells; (B): 2nd group arrow showed weak caspase 3 expression; (C) 3rd group arrow outlined moderate caspase 3 expression in few cells; (D) 4th group arrow exhibited strong caspase 3 expression. Bar = 50 µm.

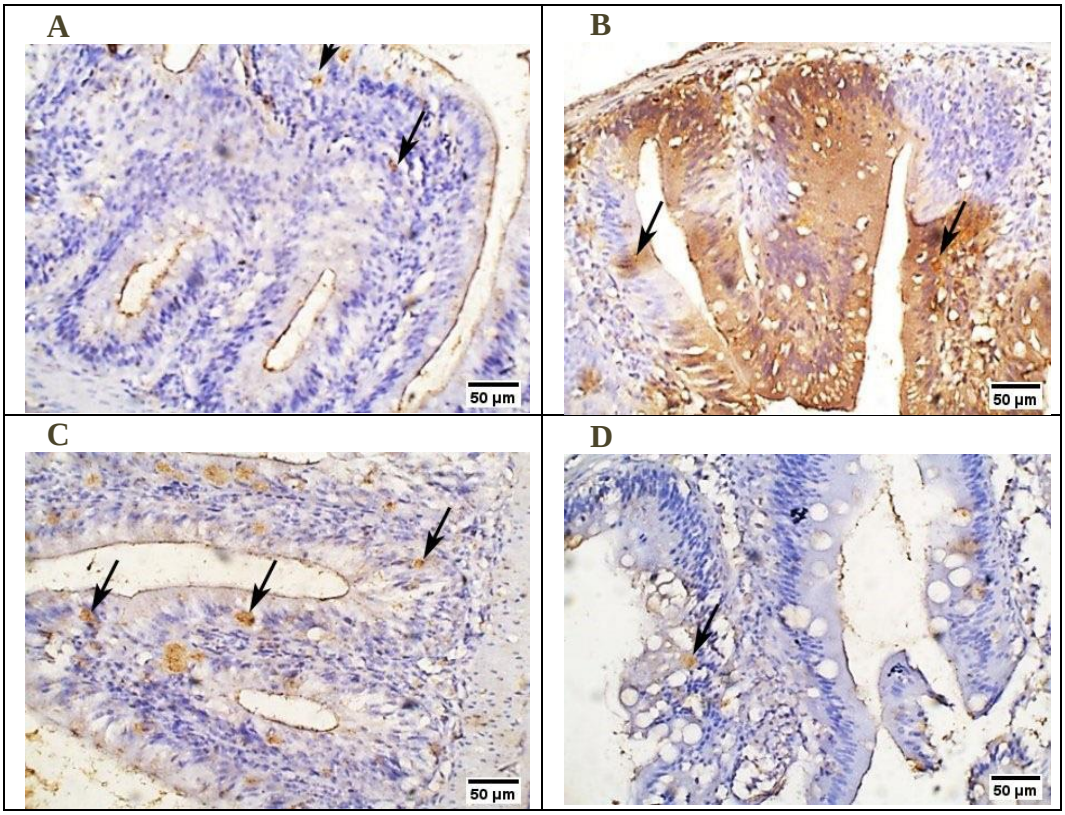

Figure 4. Graphical photomicrographs of immunohistochemical heme oxygenase 1 expression in common carp fingerlings intestinal villi.

(A): 1st group arrow delineated moderate heme oxygenase 1 expression in few cells; (B): 2nd group arrow showed strong heme oxygenase 1 expression; (C) 3rd group arrow outlined moderate heme oxygenase 1 expression in most cells; (D) 4th group arrow exhibited weak heme oxygenase 1 expression. Bar = 50 µm.

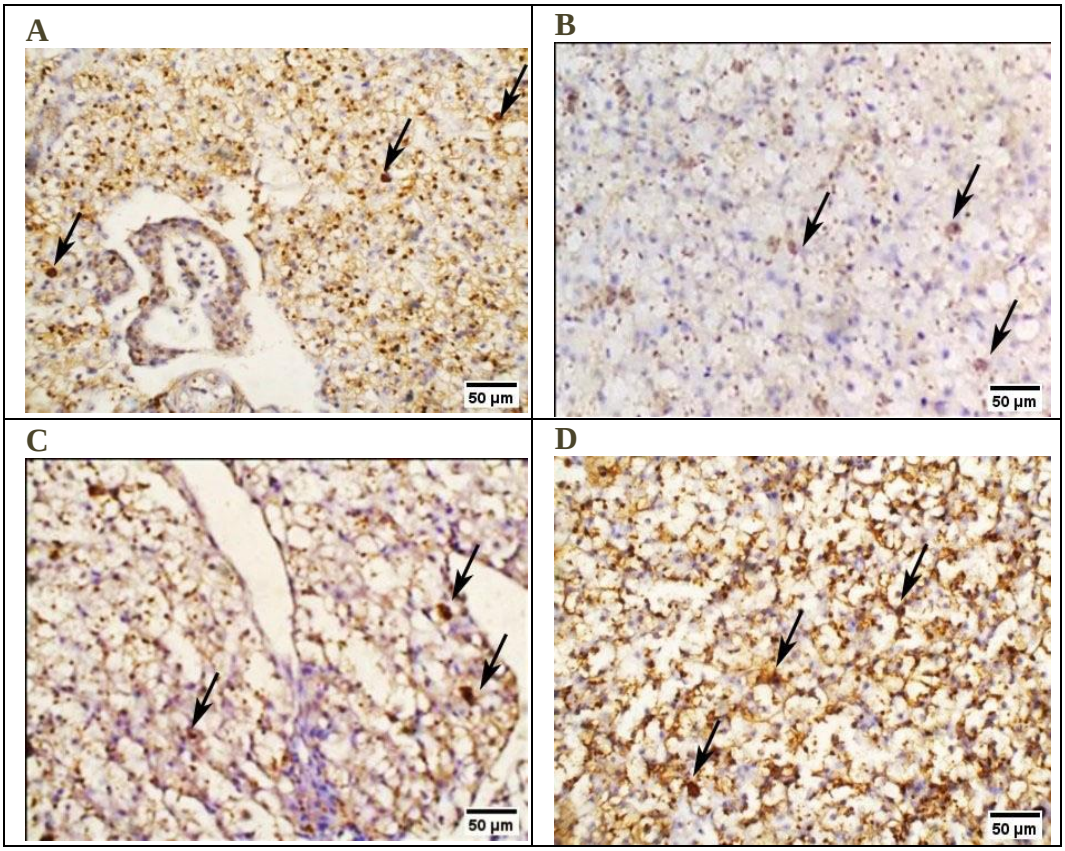

Figure 5. Graphical photomicrographs of immunohistochemical caspase 3 expression in common carp fingerlings liver.

(A): 1st group arrow delineated moderate caspase 3 expression in most cells; (B): 2nd group arrow showed weak caspase 3 expression; (C) 3rd group arrow outlined moderate caspase 3 expression in few cells; (D) 4th group arrow exhibited strong caspase 3 expression. Bar = 50 µm.

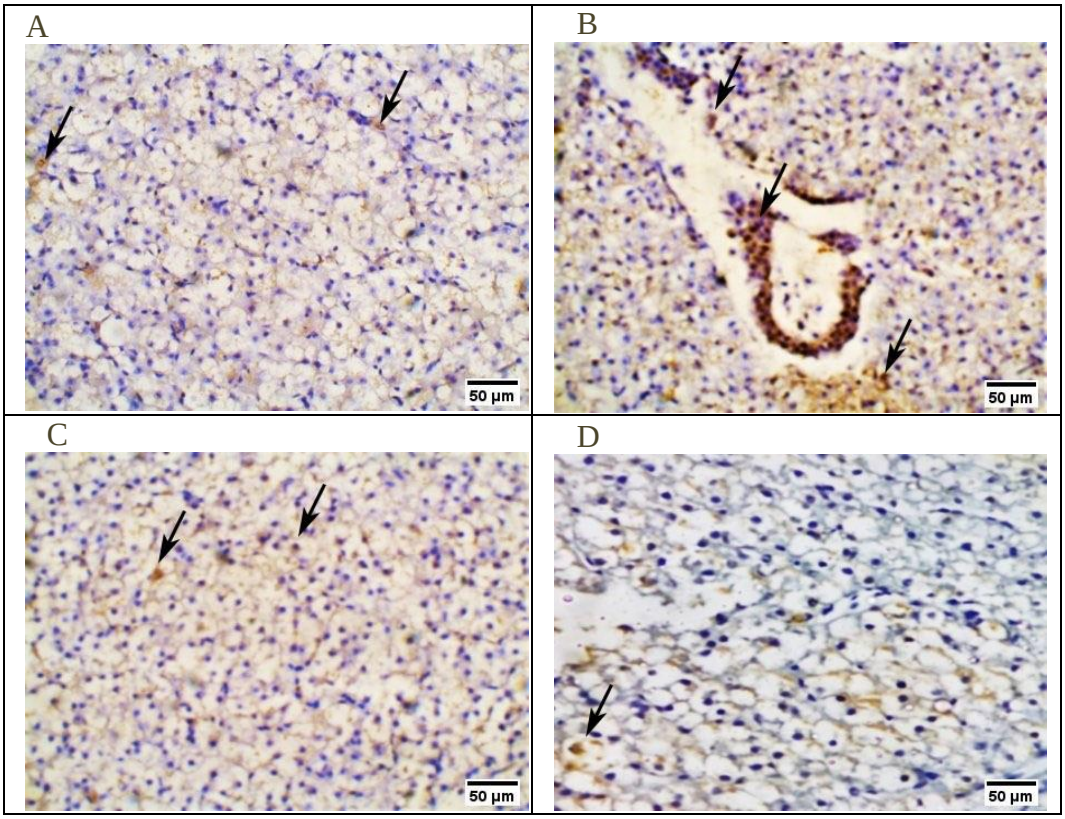

Figure 6. Graphical photomicrographs of immunohistochemical heme oxygenase 1 expression in common carp fingerlings liver.

(A): 1st group arrow delineated moderate heme oxygenase 1 expression in few cells; (B): 2nd group arrow showed strong heme oxygenase 1 expression; (C) 3rd arrow group outlined moderate heme oxygenase 1 expression in most cells; (D) 4th group arrow exhibited weak heme oxygenase 1 expression. Bar = 50 µm.

REFERENCES

Asad, F.; M.S. Mubarik; T. Ali; M.K. Zahoor; R. Ashrad and S. Qamer, 2019. Effect of organic and in-organic chromium supplementation on growth performance and genotoxicity of Labeo rohita. Saudi J. Biol. Sci., 26: 1140-1145.

Chen, W.Y.; C.J. Chen; C.H. Liu and F.C. Mao, 2009. Chromium supplementation enhances insulin signalling in skeletal muscle of obese KK/HlJ diabetic mice. J Diabetes, Obesity and Metabolism, 11: 293-303.

Cheng, H.H.; M.H. Lai; W.C. Hou and C.L. Huang, 2004. Antioxidant Effects of Chromium Supplementation with Type 2 Diabetes Mellitus and Euglycemic Subjects. Journal of agricultural and food chemistry, 52**:** 1385-1389.

De Silva, S.S. and T.A. Anderson, 1995. Fish nutrition in aquaculture, 1st edn. Chapman and Hall, London. p. 319.

Dytham, C., 2011. Choosing and Using Statistics: a Biologist's Guide, John Wiley & Sons.

Elmore, S., 2007. Apoptosis: a review of programmed cell death. Toxicol Pathol, 35: 495-516.

Farag, M.R.; M. Alagawany; M. El-Hack; A. Muhammad; T. Ayasan; D. Kuldeep; P. Amlan and K. Kumaragurubaran, 2017. Role of chromium in poultry nutrition and health: beneficial applications and toxic effects. International Journal of Pharmacology, 13: 907-915.

Gao, D.; Z. Xu; P. Qiao; S. Liu; L. Zhang; P. He; X. Zhang; Y. Wang and W. Min, 2013. Cadmium induces liver cell apoptosis through caspase-3A activation in purse red common carp (Cyprinus carpio). PloS one, 8: e83423.

Ghazi, S.; M. Habibian; M. Moeini and A.R. Abdolmohammadi, 2012. Effects of different levels of organic and inorganic chromium on growth performance and immunocompetence of broilers under heat stress. Biol Trace Elem Res., 146 (3): 309-17.

González, D.; J. Espino; I. Bejarano; J.J. López; A.B. Rodríguez and J.A. Pariente, 2010. Caspase-3 and -9 are activated in human myeloid HL-60 cells by calcium signal. Molecular and cellular biochemistry, 333 (1): 151-157

Guo, Y.; Y. Wang and B. Huang, 2020. The acute toxicity effects of hexavalent chromium in antioxidant system and gonad development to male clam Geloina coaxans. The European Zoological Journal, 87: 325-335.

Hininger, I.; R. Benaraba; M. Osman; H. Faure; A. Marie Roussel and R.A. Anderson, 2007. Safety of trivalent chromium complexes: no evidence for DNA damage in human HaCaT keratinocytes. Free Radic Biol Med, 42: 1759-1765.

Hirayama, Y.; A. Kobiyama; Y. Ochiai and S. Watabe, 1998. Two types of mRNA encoding myosin regulatory light chain in carp fast skeletal muscle differ in their 3'non-coding regions and expression patterns following temperature acclimation. J. Exp. Biol., 201: 2815-2820.

Ilic, I.R.; N.M. Stojanovic; N.S. Radulovic; V.V. Zivkovic; P.J. Randjelovic; A.S. Petrovic; M. Bozic and R.S. Ilic, 2019. The Quantitative ER Immunohistochemical Analysis in Breast Cancer: Detecting the 3 + 0, 4 + 0, and 5 + 0 Allred Score Cases. Medicina (Kaunas), 55 (8): 461.

Iskra, R. and V. Yanovych, 2013. The influence of chromium chloride consumption on lipid peroxidation and activity of the antioxidant defense in rat tissues. Biochemistry (Moscow) Supplement Series B: Biomedical Chemistry, 7: 231–236.

Khan, R.U.; N. Shabana and D. Kuldeep, 2014. Chromium: pharmacological applications in heat-stressed poultry. International Journal of Pharmacology, 10**:** 213-217.

Köktürk, M.; G. Alak and M. Atamanalp, 2020. The effects of n-butanol on oxidative stress and apoptosis in zebra fish (Danio rerio) larvae. Comparative Biochemistry and Physiology Part C: Toxicology & Pharmacology, 227**:** 108636.

Kriton, G.; K. Dimitra; G. Corraze; P.-S. Jaume; A. Adorjan and J.S. Zsuzsanna, 2018. Impact of Diets Containing Plant Raw Materials as Fish Meal and Fish Oil Replacement on Rainbow Trout (Oncorhynchus mykiss), Gilthead Sea Bream (Sparus aurata), and Common Carp (Cyprinus carpio) Freshness. Journal of Food Quality, 1717465.

Kumari, K.; A. Khare and S. Dange, 2014. The Applicability of Oxidative Stress Biomarkers in Assessing Chromium Induced Toxicity in the Fish Labeo rohita. BioMed Research International, (4): 782493.

Li, C.; L. Li; L. Jin and J. Yuan, 2018. Heme Oxygenase-1 inhibits spring viremia of carp virus replication through carbon monoxide mediated cyclic GMP/Protein kinase G signaling pathway. Fish & shellfish immunology, 79**:** 65-72.

Liang, L.; Y. Chang; X. He and R. Tang, 2015. Transcriptome Analysis to Identify Cold-Responsive Genes in Amur Carp (Cyprinus carpio haematopterus). PloS one, 10 (6): e0130526.

Lu, D.L.; Q. Ma; S.X. Sun; H. Zhang; L.Q. Chen; M.L. Zhang and Z.Y. Du, 2019a. Reduced oxidative stress increases acute cold stress tolerance in zebrafish. Comparative biochemistry and physiology. Part A, Molecular & integrative physiology, 235**:** 166-173.

Lu, D.L.; Q. Ma; J. Wang; L.Y. Li; S.L. Han; S.M. Limbu; D.L. Li; L.Q. Chen; M.L. Zhang and Z.Y. Du, 2019b. Fasting enhances cold resistance in fish through stimulating lipid catabolism and autophagy. J. Physiol., 597**:** 1585-1603.

Lukaski, H.C., 2019. Chapter 2 - Effects of chromium(III) as a nutritional supplement. In: J. B. Vincent (ed.), The Nutritional Biochemistry of Chromium (III) (Second Edition). Elsevier.

Lushchak, O.V.; O.I. Kubrak; O.V. Lozinsky; J.M. Storey; K.B. Storey and V.I. Lushchak, 2009. Chromium(III) induces oxidative stress in goldfish liver and kidney. Aquatic toxicology (Amsterdam, Netherlands), 93**:** 45-52.

Moeini, M.M.; A. Bahrami; S. Ghazi and M.R. Targhibi, 2011. The effect of different levels of organic and inorganic chromium supplementation on production performance, carcass traits and some blood parameters of broiler chicken under heat stress condition. Biological trace element research, 144**:** 715-724.

NRC, N.J.W., 2011. Nutrient requirements of fish and shrimp DC: National Academy Press.

Özdemir, S.; S. Altun and H. Arslan, 2018. Imidacloprid exposure cause the histopathological changes, activation of TNF-α, iNOS, 8-OHdG biomarkers, and alteration of caspase 3, iNOS, CYP1A, MT1 gene expression levels in common carp (Cyprinus carpio L.). Toxicology reports, 5: 125-133.

Pechova, A. and L. Pavlata, 2007. Chromium as an essential nutrient: a review. Veterinární Medicína, 52 (1): 1-18.

Poledník, L.; J. Rehulka; A. Kranz; K. Poledníková; V. Hlavác and H. Kazihnitková, 2008. Physiological responses of over-wintering common carp (Cyprinus carpio) to disturbance by Eurasian otter (Lutra lutra). Fish Physiol Biochem, 34: 223-234.

Roberts, A.P. and J.T. Oris, 2004. Multiple biomarker response in rainbow trout during exposure to hexavalent chromium. Comparative Biochemistry, Physiology Part C: Toxicology, and Pharmacology, 138**:** 221-228.

Ruangroupan, L.; T. Kitao and T. Yoshida, 1986. Protective efficacy of Aeromonas hydrophila vaccines in Nile tilapia. Veterinary Immunology and Immunopathology, 12 (1-4): 345-350.

Samanta, S.; S. Haldar and T.K. Ghosh, 2008. Production and carcase traits in broiler chickens given diets supplemented with inorganic trivalent chromium and an organic acid blend. British poultry science, 49**:** 155-163.

Suganya, M.; B.M. Gnanamangai; C. Govindasamy; M.F. Elsadek; A. Pugazhendhi; V. Chinnadurai; A. Selvaraj; B. Ravindran; S.W. Chang and P. Ponmurugan, 2019. Mitochondrial dysfunction mediated apoptosis of HT-29 cells through CS-PAC-AgNPs and investigation of genotoxic effects in zebra (Danio rerio) fish model for drug delivery. Saudi Journal of Biological Sciences, 26**:** 767-776.

Sun, X. and L.J.A. Liang, 2004. A genetic linkage map of common carp (Cyprinus carpio L.) and mapping of a locus associated with cold tolerance. Aquaculture, 238 (1): 165-172.

Takahara, T.; H. Yamanaka; A.A. Suzuki; M.N. Honjo; T. Minamoto; R. Yonekura; T. Itayama; Y. Kohmatsu; T. Ito and Z.I. Kawabata, 2011. Stress response to daily temperature fluctuations in common carp, Cyprinus carpio L. Hydrobiologia, 675**:** 65-73.

Tang, H.Y.; Q.G. Xiao; H.B. Xu and Y. Zhang, 2015. Hypoglycemic activity and acute oral toxicity of chromium methionine complexes in mice. *Journal of* Trace Elements in Medicine and Biology, 29**:** 136-144.

Tkaczewska, J.; B. Borczak, E. Piątkowska; J. Kapusta-Duch; M. Morawska and T. Czech, 2019. Effect of protein hydrolysates from carp (Cyprinus carpio) skin gelatine on oxidative stress biomarkers and other blood parameters in healthy rats. Journal of Functional Foods, 60**:** 103411.

Tkaczewska, J.; M. Morawska; P. Kulawik and M. Zając, 2018. Characterization of carp (Cyprinus carpio) skin gelatin extracted using different pretreatments method. Food Hydrocolloids, 81**:** 169-179.

Tseng, C.K.; C.K. Lin; Y.H. Wu; Y.H. Chen; W.C. Chen; K.C. Young and J.C. Lee, 2016. Human heme oxygenase 1 is a potential host cell factor against dengue virus replication. Scientific reports, 6**:** 32176.

Velma, V. and P.B. Tchounwou, 2013. Oxidative Stress and DNA Damage Induced by Chromium in Liver and Kidney of Goldfish, Carassius auratus. Biomark Insights, 8**:** 43-51.

Vincent, J.B., 2001. The bioinorganic chemistry of chromium(III). Polyhedron, 20**:** 1-26.

Vlizlo, V.; R. Iskra; I. Maksymovych; M.W. Lis and J. Wojciech, 2014. Disturbance of antioxidant protection and natural resistance factors in rats with different availabilities of trivalent chromium. Turkish Journal of Veterinary, and Animal Sciences, 38**:** 138-144.

Wajant, H. and D. Siegmund, 2019. TNFR1 and TNFR2 in the Control of the Life and Death Balance of Macrophages. Front. Cell Dev. Biol., 7: 91.

Williams, E.M.; J.P. Higgins; A.R. Sangoi; J.K. McKenney and M.L. Troxell, 2015. Androgen receptor immunohistochemistry in genitourinary neoplasms. Int Urol Nephrol, 47**:** 81-85.

دراسة حول كيميائية المناعية الخلوية لتأثير إضافة سداسي هيدرات كلوريد الكروم علي اصبعيات المبروك العادي المعرضة لبكتيريا الأيروموناس فيروني وإجهاد البرودة

احمد علي احمد

قسم صحة الأسماك ورعايتها– المعمل المركزي لبحوث الثروة السمكية– مركز البحوث الزراعية – مصر.

الملخـــــص العربـــــي

إجهاد البرودة هو تهديد رئيسي للأسماك في كل من البيئة الطبيعة والمزارع السمكية ، حيث يسبب الإجهاد التأكسدي في مختلف الأسماك. في الوقت الذي لا يزال الدور الدقيق للإجهاد التأكسدي في النفوق الناجم عن البرد غير معروف. أظهرت النتائج أن الإجهاد التأكسدي كان اكثر وضوحا في الكبد والأمعاء لإصبعيات المبروك العادي ، مما قد يؤدي إلى النفوق. ثم أجريت التجارب لتحديد التأثيرات المضادة للأكسدة ومضادات موت الخلايا المبرمج لكلوريد الكروم على تحمل البرد في إصبعيات المبروك العادي من خلال تقييم التعبير الكيميائي الهيم اكسجيناز ١ ، كاسباس ٣ في الكبد والأمعاء. تم تغذية الأسماك على أعلاف تجريبية لمدة شهرين تحتوي على كلوريد الكروم سداسي هيدرات (٠ ، ٠,٣ ، ٠,٥ ، ٠,٦ مجم / كجم) خلال فصل الشتاء. أظهرت إصبعيات المبروك العادي التي تم تغذيتها بكلوريد الكروم ٠.٣ مجم / كجم تعبيرًا ضعيفًا لـــ كاسباس ٣ وتعبيرًا قويًا للهيم أكسجيناز ١ في كل من الكبد والأمعاء مع انخفاض في الإجهاد التأكسدي وتلف الأنسجة ، وكانت اكثر تحملا للبرودة. أظهر تقييم أداء النمو تحسنًا معنويا مقارنة بالمجموعات الأخرى وأكدت هذه النتائج التأثيرات المحتملة المضادة للأكسدة ومضادات موت الخلايا المبرمج والمفيدة لكلوريد الكروم على إصبعيات المبروك العادي. كما كان أقل معدل للنفوق تم تسجيله في المجموعة الثانية مما يدل على تاثير مضادات الأكسدة لكلوريد الكروم سداسي هيدرات. بينما أظهرت المجموعة الرابعة (٠,٦ مجم / كجم) تعبيرًا قويًا عن كاسباس ٣ وتعبير ضعيف للهيم أوكسجيناز ١ في كل من الكبد والأمعاء. ونستنتج مما سبق أن تقليل الإجهاد التأكسدي سيزيد من تحمل البرد والعدوى بأيروموناس فيروني في إصبعيات المبروك العادي.