Abbassa Int. J. Aqua., Vol.13 No.(2) 2020.

257 - 277

PHENOTYPIC CHARACTERIZATION OF BACTERIAL PATHOGENS ASSOCIATED WITH NILE TILAPIA (*OREOCHROMIS NILOTICUS*) MASS MORTALITIES IN SOME EGYPTIAN FISH FARMS

Ayman A. Ammar; Salh F. Saqr; Mahmoud M. El-Adawy; Tagreed M. Nageeb; Ahmed M. Abdelwahab and Ahmed A. Ahmed.

Central Laboratory for Aquaculture Research, Agriculture Research Centre Sharkia, Egypt.

Received 25 /10 /2020 *Accepted 24 /11 /2020*

ABSTRACT

The present study was planned to investigate the most bacterial pathogens associated with the Nile tilapia mass mortality in Egyptian fish farms. The studies were carried out onto clinically diseased Nile tilapia collected from 3 localities in Egypt fish farms. Clinical examination revealed darkness of the skin, hemorrhage on the operculum, base of fins around mouth edge and anal opening. The postmortem examination showed congestion of internal organs, liver with necrotic lesion, enlarged with hemorrhagic ends and enlarged gall bladder. A total of 110 bacteriological samples were taken, 50 samples from Kafr El-Sheikh, 25 from El-behera and 35 samples from Sharkia provinces. The results of bacteriological examination revealed the presence of 78.0 bacterial isolates related to 4.0 bacterial species. The most predominant bacterial spp. was *A.veronii* 27.0 isolates (34.6%) followed by *A.hydrophila* 22.0 isolates (28.2%), *Actinobacter spp.*17 isolates (21.8%) and Streptococcus spp 12.0 isolates (15.4%).The distribution of isolates among various examined tissue and organs were; Skin 22.0 (28.2%), gills 18.0 (23.1%), liver 16 (20.5 %), kidney 12 (15.4%) and spleen 10 isolates (12.8 %). The distribution of *A.veronii* isolates were; skin 6.0 (22.2 %), gills 5.0 (18.5%), liver 4.0 (14.9%), kidney 6.0 (22.2 %) and spleen 6.0 isolates (22.2 %). The distribution of *A.hydrophila* were skin 5.0 (22.7 %), gills 5.0 (22.7 %), liver 4.0 (18.2 %), kidney 4 (18.2 %) and spleen 4.0 isolates (18.2%). The distribution of *streptococcus spp* isolates were; skin 4.0 (33.3 %), gills 4 (33.3%), liver 3.0 (25%), kidney 1.0 (8.4%) and spleen 0.0 isolates (0.0%). The distribution of *Actinobacter spp.* isolates were skin 7.0 (41.2%), gills 4.0 (23.5%), liver 5 (29.4 %), kidney 1.0 (5.9%) and spleen 0.0 isolates (0.0%).

Keywords: *Aeromonas Veronii, Aeromonas hydrophila,* streptococcus spp, Actinobacter spp , Nile tilapia.

INTRODUCTION

Fish and fish products are the hope to solve human nutritional problems in Egypt. One of the major threatening problems faced by the aquaculture industries is the development of bacterial diseases that causes severe financial loss .Fish diseases caused by bacterial, parasites and fungal infection causes severe economic losses to fish industries under Egyptian conditions. (Saad *et al.*, 2014). Fish diseases has always been perceived as a result of interaction of three main factors; host, pathogen and environment. Having it affecting both pathogen load and host immunity; the environmental conditions has always been viewed as the principal determining factor in the development of disease (Saeed and Shaker, 2008). Bacterial diseases are considered as one of the most important problems facing the aquaculture industry; it has been estimated that 10% of fish loss in aquaculture is due to disease and more than 50% of these losses are due to bacterial agents (Freund *et al*., 1990). A.*veronii* has been reported as a cause of epizootic ulcerative syndrome and hemorrhagic septicaemia in fishes (Cai *et al.*, 2012). The most common bacterial pathogens of tilapia include *Streptococcus sp., Flavobacterium columnare, Aeromonas hydrophila* and *Edwardsiella tarda;* (Iregui *et al.*, 2004; Klesius *et al.*, 2008). The genus Acinetobacter is ubiquitous in nature and is frequently found in soil, water and dry environments. *Acinetobacter* is a group of Gram-negative, aerobic, nonmotile bacillus that includes seven named and nine unnamed genomospecies. Some *Acinetobacter* species, especially *Acinetobacter baumannii*, are important pathogens that are resistant to many antibiotics (Blossom and Srinivasan, 2008 and Peleg *et al*., 2008). The objectives of this study is to determine the main bacterial pathogens associated with phenomena of tilapia mass mortality in Egyptian fish farms.

MATERIALS AND METHODS

Fish sample:

This study was carried-out on random samples of private fish farms. Three localities were the area of this study regarding to their importance in farmed fish production in Egypt which related to Kafr El-Sheikh, El-behera and Sharkia provinces.

Clinical examination:

Clinical examination was performed to determine the clinical abnormalities indicating infectious fish diseases. Fish were observed for any abnormalities including hemorrhages, erosions, abdominal distention and ulcer at any part of the body and other clinical changes (Austin and Austin, 1993).

Postmortem examination:

Examination of internal organs was done. Fish were placed in disinfected dissection pan on its right side. Disinfection of skin was performed using 70% ethyl alcohol. The first cut was made in the front of the anus through the abdominal wall with sterile scissor. The second cut was made perpendicular to the first directly behind the branchial cavity. The third cut was from the anus to the head parallel to the middle line where the abdominal wall was removed and the internal organs become visible and examined for detection of any abnormalities as changes on color, size, hemorrhages, ascetic fluid and other deformity (Austin and Austin, 1993).

Bacteriological examination:

Total number of 110 samples were collected from clinically diseased Nile tilapia under aseptic condition**;** samples were taken from skin, gills, liver, kidney and spleen. The surface of internal organs was sterilized with heated spatula; sterile bacteriological loop was inserted through the organs. All samples taken were inoculated into Tryptic Soy broth, incubated at 28°C for 24-48 hrs, and then the inoculums were streaked over Tryptic soya agar (TSA). The purified colonies were picked up and inoculated onto semi-sold media for further identification. (Austin and Austin, 1993).

Identification of bacterial isolates:

Biochemical test:

The obtained pure colonies were identified according to (**Austin and Austin, 1993).** Colonial morphology, slide film was stained with grams stains for microscopically examination and description of the shape and arrangement of bacteria. Cytochrom-Oxidase test applied on TSA agar to differentiate between members of Enterobacteriacea groups and other gram -negative rods bacteria. Oxidation/fermentation basal medium (O/F) was prepared**.**

API-20E microbiological identification:

API-20E microbial identification kits (BioMerieux) were used to perform 20 biochemical tests at a time. The sample was prepared by suspending a single colony from a fresh culture into 5 mL of sterile saline solution. Then the suspension was carefully inoculated in all the tube sections according to the manufacturer instructions. All incubations were done at 28°C.

RESULTS

Clinical signs:

The moribund Nile tilapia fish were collected from ponds at freshwater fish farms in Kafr El-Sheikh, El-behera and Sharkia provinces. Where collected fish had developed similar pathological signs. The principle clinical signs of the affected Nile tilapia were red area on body surface and petechial hemorrhage on different sides of the body surface (photo1&2). At later stage of infection, fish stop feeding and died.

Postmortem examination:

PM examination showed congestion of internal organs, liver with necrotic lesion, enlarged with hemorrhagic ends and enlarged gall bladder (photo 3 &4).

Bacteriological examination:

A total of 110 bacteriological samples were taken 50 samples from Kafr El-Sheikh, 25 from El-behera and 35 samples from Sharkia provinces (Table 6). After 24 h of incubation under aerobic conditions, colonies appeared on the Tryptic soya agar plate. For 49 isolates the colonies were round in shape with 1–3 mm diameter size, creamy white color onto TSA, dark green color onto Aeromonas base agar, yellow color onto TCBs, 27 isolates were esculin hydrolysis positive and other 22 isolates were negative. For 12 isolate colonies were pin heeded, white color onto TSA, not grow either onto Aeromonas base, TCBs. For 17 isolates colonies were slight grow onto TSA, not grow either onto Aeromonas base or TCBs. All the colonies were tested by Gram's staining method and identified with biochemical and phenotypic analysis using API 20 E. (Table 1) (photo 5& 6& 7). The distribution of isolates among different localities were summarized in (Table 6).

Analytic profile index:

The phenotypic identification protocol revealed that, 27 isolates were positive for Oxidation of ONPG, Arginine dihydrolase, Citrate utilization, Indole production, Acetoin production, Gelatin hydrolysis, Glucose and Sucrose fermentation. The strain were negative for Lysine decarboxylase, Ornithine decarboxylase, Urea hydrolysis, Inositol, Sorbitol, Rhamnose, Melibiose, Arabinose and Amygdalin. Based on the morphological and biochemical test. The suspected strains were presumed as *A. Veronii* Table (2) photo (8). The phenotypic identification protocol revealed that, 22 isolates were positive for Oxidation of ONPG, Arginine dihydrolase, Lysine decarboxylase, Citrate utilization, Indole production, Acetoin production, Gelatin hydrolysis, Glucose and Sucrose fermentation. The strain were negative for Ornithine decarboxylase, Urea hydrolysis, Inositol, Sorbitol, Rhamnose, Melibiose, Arabinose and Amygdalin. Based on the morphological and biochemical test the suspected strains were presumed as *A. hydrophila* Table (2) and photo (9). The phenotypic identification protocol revealed that, 17 isolates were positive

for Citrate utilization, VP and tryptophan hydrolysis and negative for Oxidation of ONPG, Arginine dihydrolase, Lysine decarboxylase, Ornithine decarboxylase, Indole production, Acetoin production, Gelatin hydrolysis, Glucose and Sucrose fermentation, Urea hydrolysis, Inositol, Sorbitol, Rhamnose, Melibiose, Arabinose and Amygdalin. Based on the morphological and biochemical test the suspected strains were presumed as *Actinobacter spp*. Table (2), photo (10). Biochemical identification revealed that 12 isolates were gram positive cocci arranged in chain, negative for catalase and oxidase test the suspected stain were presumed as Streptococcus spp Table (1).The results of bacteriological examination revealed the presence of 78 bacterial isolates related to 4 bacterial species. The most predominant bacterial spp. was *A.veronii* 27 isolates (34.6%) followed by *A.hydrophila* 22 isolates (28.2 %) and *Actinobacter spp.* 17 isolates (21.8 %) then *Streptococcus spp*. 12 isolates (15.4%) Table (3). The distribution of isolates among various examined tissue and organs were; Skin 22 isolates (28.2%), gills 18 isolates (23.1%), liver 16 isolates (20.5 %), kidney 12 isolates (15.4%) and spleen 10 isolates (12.8 %) Table (4). The distribution of *A.veronii* isolates among various examined tissue and organs of clinically diseased Nile tilapia were; skin 6 isolates (22.2 %), gills 5 isolates (18.5%), liver 4 isolates (14.9%), kidney 6 isolates (22.2%) and spleen 6 isolates (22.2%) as shown in Table (5). The distribution of *A.hydrophila* isolates among various examined tissue and organs of clinically diseased Nile tilapia were ; skin 5 isolates (22.7 %), gills 5 isolates (22.7 %), liver isolates 4 (18.2 %), kidney 4 isolates (18.2%) and spleen 4 isolates (18.2%) as shown in Table (5). The distribution of *streptococcus spp.* isolates among various examined tissue and organs of clinically diseased Nile tilapia were; skin 4 isolates (33.3 %), gills 4 isolates (33.3%), liver 3 isolates (25%), kidney 1 isolates (8.4 %) and spleen 0.0 isolates (0.0%) as shown in Table (5). The distribution of *Actinobacter spp.* isolates among various examined tissue and organs of clinically diseased Nile tilapia were; skin 7 isolates (41.2%), gills 4 isolates (23.5%), liver 5 isolates (29.4 %), kidney 1.0 isolates (5.9%) and spleen 0.0 isolates (0.0%) as shown in Table (5).

DISCUSSION

The Nile tilapia, O. niloticus, is a cichlid species native to Africa, due to its given advantages such as rapid reproduction rate and growth, omnivorous feeding, and hardiness, has been used in aquaculture in different parts of the world including America, Africa, and Asia. In the present study The principle clinical signs of the affected Nile tilapia were red area on body surface and petechial hemorrhage on different sides of the body surface (photo1&2). It is well documented that several Aeromonas spp. were involved as a cause of diseases in aquatic habitat (wild and farmed freshwater/marine fish species), mass mortalities and in turn great economic losses to aquaculture sector (Eissa *et al.*, 2015). Moreover *A. veronii* previously described as a cause of hemorrhagic septicemia and EUS (Cai *et al.*, 2012) among various fish species worldwide (Eissa *et al*., 2015; Cai *et al*., 2012; Sreedharan *et al.*, 2011 and Nawaz *et al*., 2006). PM examination showed congestion of internal organs, liver with necrotic lesion, enlarged with hemorrhagic ends and enlarged gall bladder (photo 3 &4) The same reported by (Eissa *et al.*, 2015; Jagoda *et al.*, 2014; Cai *et al.*, 2012 and Wahli *et al.*, 2005). (Turska-Szewczuk *et al.* 2014). Contribution of several factors of extracellular product in the complex mechanism of Aeromonas infection pathogenesis including hemolysins, cytotonic and cytotoxic enterotoxins, proteases, lipases, and leucocidins. Aeromonads are Gram-negative rods ubiquitous in aquatic environments (Janda and Abbott, 2010; Beaz Hidalgo and Figueras 2012). Motile aeromonad septicaemia (MAS), with mesophilic, motile Aeromonas species implicated in its development, is probably the most common bacterial disease in freshwater aquarium fish (Lewbart, 2001). It is often an opportunistic infection, characterized by non-specific signs such as fin rot, ulceration, haemorrhages, exophthalmia and dropsy. *Aeromonas hydrophila* is the most cited motile Aeromonas species classically linked to MAS in freshwater fish (Hettiarachchi and Cheong, 1994; Nielsen *et al.*, 2001 and Austin, 2011). In contrast, we found

A. veronii 27 isolates (34.6%) to be the predominant species followed by Aeromonas hydrophila 22 isolates (28.2) which is in agreement with others who reported the dominance of *A. veronii* among fish pathogenic aeromonad isolates following molecular identification (Sreedharan *et al.*, 2011, 2013; Hu *et al.*, 2012 and Yi *et al.*, 2013). This difference could possibly be related to the host species selected and the geographical location. The identification of aeromonads is fraught with numerous difficulties due to the phenotypic, serological and genotypic heterogeneity existing within the genus. Discrepancies in identification of Aeromonas resulting from poor correlation between phenotypic and genetic identification schemes have been well documented (Kozin´ ska *et al.*, 2014 and Beaz-Hidalgo *et al.*, 2010). Biochemical identification revealed that 12 isolates were gram positive cocci arranged in chain, negative for catalase and oxidase test the suspected stain were presumed as Streptococcus spp Table (1) The most common bacterial pathogens of tilapia include *Streptococcus sp.*, *Flavobacterium columnare*, *Aeromonas hydrophila* and *Edwardsiella tarda*; and within parasitic infections are found *Ichthyophthirius multifiliis* and *Trichodina sp*., (Iregui *et al.*, 2004 and Klessius *et al.*, 2008). Of note, infections by the genus Streptococcus sp., are perhaps the most important health problem in farmed tilapia, with serious economic losses that were estimated at 250 million USD in 2008 globally (Klesius *et al.*, 2008). The most significant Streptococcus species that cause disease in the tilapia industry worldwide are *S. iniae, S. agalactiae, S. dysgalactiae and Lactococcus garviae* (Evans *et al.*, 2006 and Netto *et al.*, 2011). The phenotypic identification protocol revealed that, 17 isolates were presumed as *Actinobacter spp*. Table (2), photo (10).The genus Acinetobacter is ubiquitous in nature and is frequently found in soil, water and dry environments. Acinetobacter is a group of Gram-negative, aerobic, nonmotile bacillus that includes seven named and nine unnamed genomospecies. Some Acinetobacter species, especially *Acinetobacter baumannii*, are important pathogens that are resistant to many antibiotics (Blossom and Srinivasan, 2008

and Peleg *et al*., 2008). On the last years, there have been some reports on the incidence of infection of fish by Acinetobacter species; for example, channel catfish *(Ictalurus punctatus)* and snakehead fish (Channa striatus) infected with *A.baumannii* (Lu *et al*., 2008 and Rauta *et al*., 2011) and rainbow trout (Oncorhynchus mykiss) infected with Acinetobacter johnsonii (Kozińska *et al*., 2014). There were also a few reports concerning other Acinetobacter spp. isolated from fish (Coz-Rakovac *et al*., 2002 and Yonar *et al*., 2010).

Table 1. Morphological & biochemical characters of bacterial pathogens isolated from clinically diseased Nile tilapia.

Test	Morphological Character			
	A.veronii	***A.hydrophila***	**Streptococus spp**	**Actinobacter spp**
Gram stain	-ve	-ve	+ve	-ve
Shape	Rod	Rod	Cocci	Cocci
Motility	+	+	-	-
TSA	Creamy white	Creamy white	Pin point	Light growth
Aeromonas base media	Green colone	Green colone	-	-
TCBS	Yellow colone	Yellow colone	-	-
Esculin agar	+	-	+	-
Oxidase	+	+	_	_
O/F	+/+	+/+	-	F

Table 2. Phenotypic character of bacterial pathogens isolated from clinically diseased Nile tilapia using API-20E kits.

Test	Substrate	*Aeromonas veronii*	*Aeromonas hydrophila*	*Acintobacter sp.*
ONPG	ONPG	+	+	-
ADH	Arginine	+	+	-
LDC	Lysine	–	+	-
ODC	Ornithine	–	-	-
CIT	Citrate	+	+	+
H2S	Nathiosulphate	–	-	-
URE	Urea	–	-	-
TDA	Tryptphan	+	+	+
IND	Tryptophan	+	+	-
VP	Na pyruvate	+	+	+
GEL	Charcoal gelatin	+	+	-
GLU	Glucose	+	+	-
MAN	Mannitol	+	+	-
INO	Inositol	–	-	-
SOR	Sorbitol	–	-	-
RHA	Rhamnose	–	-	-
SAC	Sucrose	+	+	-
MEL	Melibiose	–	-	-
AMY	Amygdalin	–	-	-
ARA	Arabinose	–	-	-
OXI	Oxidase	+	+	-

Table 3. Incidence of isolated bacterial strains.

No of samples	No of isolates	*A. veronii*	*A. hydrophila*	*Streptococcus spp*	*Actinobacter spp*
110	78	27	22	12	17
%	70.9	34.6	28.2	15.4	21.8

Table 4. Distribution of isolated strains in different examined tissue and organs.

Organs	Samples	Isolates	% to Total isolates
Skin	22	22	28.2 %
Gills	22	18	23.1 %
Liver	22	16	20.5 %
Kidney	22	12	15.4 %
Spleen	22	10	12.8 %
Total	110	78	70.9 %

Table 5. Collective data of obtained isolates among tissue and organs.

Organs	*A. veronii*		*A. hydrophila*		*Streptococcus. spp*		Actinobacter. *spp*	
	No	%	No	%	No	%	No	%
Skin	6	22.2	5	22.7	4	33.3	7	41.2
Gills	5	18.5	5	22.7	4	33.3	4	23.5
Liver	4	14.9	4	18.2	3	25	5	29.4
Kidney	6	22.2	4	18.2	1	8.4	1	5.9
Spleen	6	22.2	4	18.2	-	-	-	-
Total	27	34.6%	22	28.2%	12	15.4%	17	21.8%

Table 6. Distribution of samples and isolates among different localities.

Locality	No of Samples	No Isolates	% of Infection
Kafr El-Sheikh	50	32	64
El-behera	25	19	76
Sharkia	35	27	77
Total	110	78	70.9

Photo1. Clinically diseased Nile tilapia showing hemorrhage and congestion around mouth.

Photo 2. Clinically diseased Nile tilapia showing hemorrhage at caudal peduncle.

Photo 3. postmortem of clinically diseased Nile tilapia showing necrotic lesion on liver.

Photo 4. postmortem of clinically diseased Nile tilapia showing enlarged liver with hemorrhagic end and enlarged gall bladder.

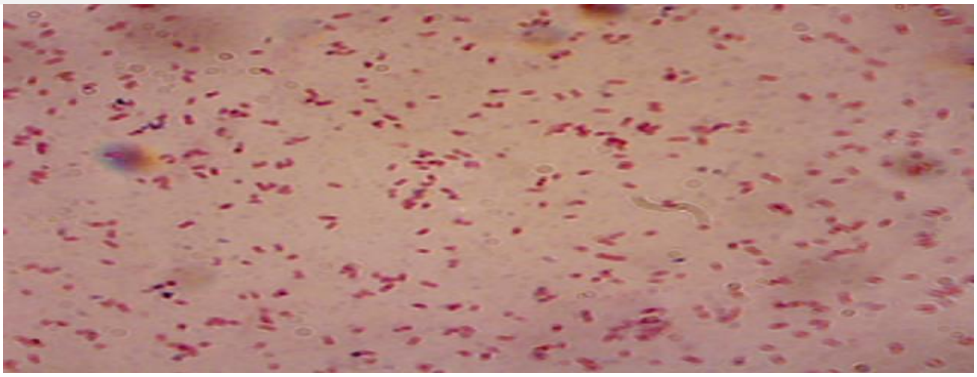

Photo 5. Gram –ve bacilli *Aeromonas spp.* (oil immertion lens 100x).

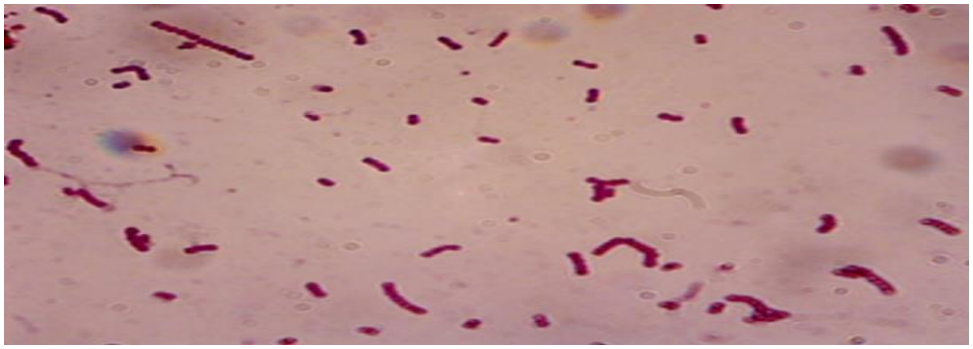

Photo 6. Gram +ve cocci *Streptococcus sp*. (oil immersion lens 100x).

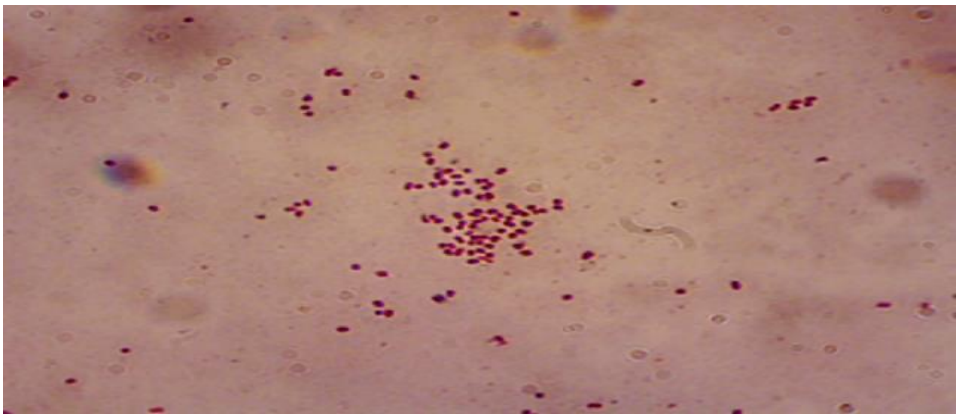

Photo 7. Gram –ve cocci *Acintobacter sp*. (oil immertion lens 100x).

Photo 8. API 20 E Confirmatory for *Aeromonas veronii.*

Photo 9. API 20 E Confirmatory for *Aeromonas hydrophila.*

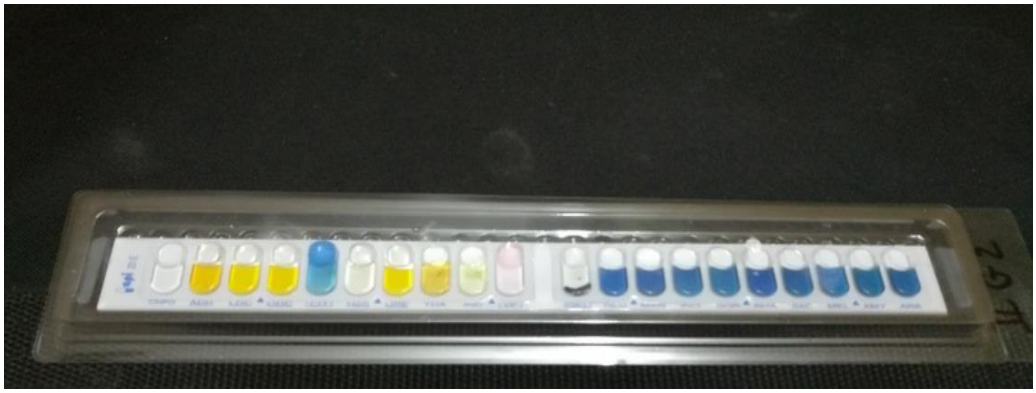

Photo 10. API20E Confirmatory for *acintobacters.spp.*

REFERENCES

Austin, B., 2011. Taxonomy of bacterial fish pathogens. Vet Res 42: 20.

Beaz-Hidalgo, R; A. Alperi; N. Buján; J.L. Romalde and M.J. Figueras, 2010. Comparison of phenotypical and genetic identification of Aeromonas strains isolated from diseased fish. Syst Appl Microbiol., 33: 149−153.

Austin, B. and D.A. Austin, 1993. Bacterial fish pathogen; Diseases in farmed and wild fish 2nd Ed. Printed and bound in Great Britain Hartonlls, Bedmen.

Beaz-Hidalgo, R. and M.J. Figueras, 2012. Molecular detection and characterization of furunculosis and other Aero - monas fish infections. In:Carvalho ED, David GS, Silva RJ (eds) Health and environment in aquaculture. InTech, Rijeka, p 97−132.

Blossom, D.B. and A. Srinivasan, 2008. Drug-Resistant Acinetobacter baumannii-calcoaceticus complex: An emerging nosocomial pathogen with few treatment options. Infectious Diseases in Clinical Practice, 16, 1–3. https://doi.org/10.1097/ipc.0b013e3181635def.

Cai, S.H; Z.H. Wu; J.C. Jian; Y.S. Lu and J.F. Tang., 2012. Characterization of pathogenic Aeromonas veronii bv. veronii associated with ulcerative syndrome from Chinese long snout catfish (Leiocassis longirostris Günther). Braz. J. Microbiol. 43: 382– 388.

Coz-Rakovac, R; I. Strunjak-Perovic; N.T. Popovic; M. Hacmanjek; B. Simpraga and E. Teskeredzic, 2002. Health status of wild and cultured sea bass in the Northern Adriatic Sea. Veterinarni Medicina, 47: 222–226.

Eissa, I.A.M; Maather; El-lamei; Mona; Sherif; Desuky; E. Mona; Zaki and M. Bakry, 2015. Aeromonas veronii biovar sobria a Causative Agent of Mass

Mortalities in Cultured Nile Tilapia in El-Sharkia governorate, Egypt. Life Sci. J., 12 (5).

Evans, J.J.; D.J. Pasnik; P.H. Klesius and C.A Shoemaker, 2006. Identification and epidemiology of Streptococcus iniae and Streptococcus agalactiae in tilapia, Oreochromis spp. International Symposium on Tilapia in Aquaculture 7. CharlesTown, WV, USA, American Tilapia Association, pp. 25-42.

Freund, J.D.; R.M. Durborow; J.R. Macmillan; M.D. Crosby; T.L. Wellborn; P.W. Taylor and T.L. Schwedler, 1990. Using Diagnostic Laboratory Records to Monitor Occurrence of Enteric Septicemia of Channel Catfish in Mississippi. Journal of Aquatic Animal Health, 2 (3): 207-211.

Hettiarachchi, D.C. and C.H. Cheong, 1994. Some characteristics of Aeromonas hydrophila and Vibrio species isolated from bacterial disease outbreaks in ornamental fish culture in Sri Lanka. J. Natl. Sci. Counc. Sri Lanka, 22: 361−369.

Hu, M; N. Wang; Z.H. Pan; Lu; Y.J. Liu, 2012. Identity and virulence properties of Aeromonas isolates from diseased fish, healthy controls and water environment in China. Lett. Appl. Microbiol., 55: 224−233.

Iregui, C.A.; E. Hernández; A.P. Jiménez; E.A. Pulido; A.L. Rey; J. Comas; L.C. Peña and M. Rodríguez, 2004. Primer Mapa Epidemiológico de las lesiones y enfermedades de los peces en Colombia [First epidemiological map of lesions and diseases of fish in Colombia]. Universidad Nacional de Colombia, MADR, Bogotá DC, Colombia.

Jagoda, S.S.; T.G. Wijewardana; A. Arulkanthan; Y. Igarashi; E. Tan; S. Kinoshita; S. Watabe and S. Asakawa, 2014. Characterization and antimicrobial susceptibility of motile aeromonads isolated from

freshwater ornamental fish showing signs of septicaemia. Dis. Aquat. Org., 109: 127–137.

Janda, J.M. and S.L. Abbott, 2010. The genus Aeromonas:taxonomy, pathogenicity, and infection. Clin. Microbiol. Rev., 23: 35−73.

Klesius, P.H.; C.A,Shoemaker and J.J. Evans, 2008. Streptococcus: A worldwide fish health problem. 8th International Symposium on Tilapia in Aquaculture. Cairo, 83-107.

Kozińska, A.; E. Paździor; A. Pękala and W.W. Niemczuk, 2014. Acinetobacter johnsonii and Acinetobacter lwoffii - the emerging fish pathogens. Bulletin of the Veterinary Institute in Pulawy, 58: 193–199.

Lewbart, G.A., 2001. Bacteria and ornamental fish. Semin Avian Exotic Pet Med, 10: 48−56.

Lu, X.; D. Xiong; Z. Gu; X. Zhen; C. Chen; J. Xie and P. Xu, 2008. Recovery of Acinetobacter baumannii from diseased channel catfish (Ictalurus punctatus) in China. Aquaculture, 284: 285–288.

Nawaz, M.S.; K. Sung; S.A. Khan; A.A. Khan and R.S. Steele, 2006. Biochemical and molecular characterization of tetracycline-resistant A*eromonas veronii* isolates from catfish. Appl. Environ. Microbiol., 72: 6461–6466.

Netto, L.N.; C.A. Leal and H.C. Figueiredo, 2011. Streptococcus dysgalactiae as an agent of septicaemia in Nile tilapia, Oreochromis niloticus (L.), Journal of Fish Diseases, 34 (3): 251-254.

Nielsen, M.E; L. Hoi; A.S. Schmidt; D. Qian; T. Shimada; J.Y. Shen and J.L. Larsen, 2001. Is Aeromonas hydrophila the dominant motile Aeromonas species that causes disease outbreaks in aquaculture production in the Zhejiang Province of China? Dis Aquat. Org., 46: 23−29.

Peleg, A.Y; H. Seifert and D.L. Paterson, 2008. Acinetobacter baumannii: Emergence of a successful pathogen. Clinical Microbiology Reviews, 21, 538–582. https://doi.org/10.1128/CMR.00058-07.

Rauta, P.R.; K. Kumar and P.K. Sahoo, 2011. Emerging new multi-drug resistant bacterial pathogen, Acinetobacter baumannii associated with snakehead Channa striatus eye infection. Current Science, 101: 548–553.

Saad, T.T.; A. Sara; Ketkat; Fardous and A. Mohamed, 2014. Changes associated with pseudomonas infection in cultured Oreochromis species and its relations to economic losses of fish production farms. Am. J. of Life Science research, 2: 238-252.

Saeed, S.M. and I.M. Shaker, 2008. Assessment of heavy metals pollution in water and sediments and their effect on Oreochromis niloticus in the northern delta lakes, Egypt. in 8 International Sy th mposium on Tilapia in Aquaculture. Citeseer.

Sreedharan, K.; R. Philip and I.S.B. Singh, 2011. Isolation and characterization of virulent Aeromonas veronii from ascetic fluid of oscar (Astronotus ocellatus) showing signs of infectious dropsy. Dis. Aquat. Org., 94 (1): 29–39.

Sreedharan, K.; R. Philip; Bright; I.S. Singh, 2013. Characterization and virulence potential of phenotypically diverse Aeromonas veronii isolates recovered from moribund freshwater ornamental fishes of Kerala, India. Antonie Leeuwenhoek, 103: 53−67.

Turska-Szewczuk, Anna; Duda; A. Katarzyna; Schwudke; Dominik; A. Kozinska; A. Pekala; Holst and Otto, 2014. Structural Studies of the Lipopolysaccharide from the Fish Pathogen Aeromonas veronii Strain Bs19, Serotype O16. Mar. Drugs, 12: 1298–1316.

Wahli, T.; S.E. Burr; D. Pugovkin; O. Mueller and J. Frey, 2005. Aeromonas sobria, a causative agent of disease in farmed perch, Perca fluviatilis L. J. Fish Dis., 28: 141– 150.

Yi, S.W.; M.J. You; H.S. Cho; C.S. Lee; J.K. Kwon and G.W. Shin, 2013. Molecular characterization of Aeromonas species isolated from farmed eels (Anguilla japonica). Vet Microbiol 164: 195−200Kozin´ ska A (2007) Dominant pathogenic species of motile aeromonads isolated from diseased and healthy fish cultured in Poland. J. Fish Dis., 30: 293−301.

Yonar, M.E; M. Karahan; N.I. Kan; S. Yonar; N. SağLam and O. Torul, 2010. A study of Acinetobacter sp. infection in some cultured rainbow trout (Oncorhynchus mykiss) in Kahramanmaras. Journal of FisheriesSciences.com, 4: 287–293.

التوصيف الظاهري للميكروبات البكتيرية المرتبطة بنقوق الاسماك الجماعي لأسماك البلطي النيلي في بعض المزارع السمكية في مصر

ايمن عمار، صالح صقر، محمود محمد العدوى، تغريد محمد نجيب،
احمد محمد عبد الوهاب، احمد على احمد

المعمل المركزي لبحوث الثروة السمكية– مركز البحوث الزراعية – مصر.

الملخـــــــص العربـــــي

أجريت الدراسة الحالية للتعرف على أهم مسببات الامراض البكتيرية المرتبطة بظاهره النقوق الجماعي لأسماك البلطي النيلي في بعض المزارع السمكية في مصر فقد تم تجميع العينات من ثلاث محافظات (الشرقية – البحيرة– كفر الشيخ). أوضحت الأعراض الإكلينيكية للأسماك المصابة طبيعيا وجود انزفه واحتقان في الخياشيم والغطاء الخيشومي والزعانف وفتحتي الفم والشرج. كما أوضحت الصفة التشريحية للأسماك المصابة طبيعيا وجود احتقان بالأعضاء الداخلية، وكان الكبد متضخم وبه تتكرز كما كان هناك تضخم بالمرارة. تم اخذ ١١٠ مسحه بكتريه ٥٠ من محافظه كفر الشيخ و٢٥ من البحيرة و٣٥ من الشرقية. اشارت الدراسة الى وجود ٧٨ عزله بكتيرية تنتمى الى ٤ فصائل بكتيرية وكانت نتائج العترات كالتالي: البكتيريا السائدة كانت الايروموناس فيرونا ٢٧ عترة بكتيرية بنسبة إصابة ٣٤,٦ % يليها الايروموناس هيدروفيلا ٢٢ عترة بكتيرية بنسبة إصابة ٢٨,٢ % ثم الاكتنوبكتر ١٧ عترة بكتيرية بنسبة إصابة ٢١,٨% ثم الاستربتوكوكس ١٢ عترة بكتيرية بنسبة إصابة ١٥,٤%. أوضحت الدراسة مدى تواجد الميكروبات داخل أنسجة اسماك البلطي النيلي ووجد أن الجلد ٢٢ عتره (٢٨,٢%) يله الخياشيم ١٨ عتره (٢٣,١%) والكبد ١٦ عتره (٢٠,٥ %) والكلى١٢ عتره ١٥,٤%) ثم الطحال ١٠ عتره (١٢,٨%). أما بالنسبة إلى الايرموناس فيرونا فكان نسبة تواجده داخل الانسجة والاعضاء كالتالي: الجلد ٦ عتره (٢٢,٢ %) الخياشيم ٥ (١٨,٥ %) والكبد ٤ (١٤,٩%) والكلى ٦ (٢٢,٢%) والطحال ٦ (٢٢,٢%). أما بالنسبة إلى الايرموناس هيدروفيلا فكان نسبة تواجده داخل الانسجة والاعضاء كالتالي: الجلد ٥ عتره (٢٢,٧ %) الخياشيم ٥ (٢٢,٧ %) والكبد ٤ (١٨,٢%) والكلى ٤ (١٨,٢ %) والطحال٤ (١٨,٢ %). أما بالنسبة إلى الاستربتوكوكس فكان نسبة تواجده داخل الانسجة والاعضاء كالتالي: الجلد ٤ عتره (٣٣,٣ %) الخياشيم ٤ (٣٣,٣ %) والكبد ٣ (٢٥ %) والكلى١ (٨,٤%) والطحال صفر (٠,٠ %). أما بالنسبة إلى الاكتنوبكتر فكان نسبة تواجده داخل الانسجة والاعضاء كالتالي: الجلد ٧ عتره (٤١,٢ %) الخياشيم ٤(٢٣,٥ %) والكبد ٥ (٢٩,٤ %) والكلى ١ (٥,٩ %) والطحال صفر (٠,٠%).